




## Coronavirus Disease-19 (COVID-19) Presenting with Severe Acute Pancreatitis: A Case Report from Iran

Maryam Jameshorani<sup>1,2</sup> , Mahdiyeh Meydanloo<sup>2</sup> , Sattar Jafari<sup>1,2</sup> ,  
Saeed Mansouri Hashchin<sup>2</sup> , Mohammad Jafari<sup>3</sup> , Negin Parsamanesh<sup>1\*</sup> 

1. Zanzan Metabolic Diseases Research Center, Zanzan University of Medical Sciences, Zanzan, Iran
2. Dept. of Internal Medicine, School of Medicine, Zanzan University of Medical Sciences, Zanzan, Iran
3. Isfahan Gastroenterology and Hepatology Research Center, Isfahan University of Medical Sciences, Isfahan, Iran

### Article Info

 [10.30699/jams.30.140.295](https://doi.org/10.30699/jams.30.140.295)

Received: 2021/01/14;

Accepted: 2021/06/24;

Published Online: 01 Apr 2022;

Use your device to scan and read the article online



### Corresponding Information:

**Negin Parsamanesh,**  
Zanzan Metabolic Diseases Research  
Center, Zanzan University of Medical  
Sciences, Zanzan, Iran  
E-Mail: [neginparsa.684@gmail.com](mailto:neginparsa.684@gmail.com)



Copyright © 2022. This is an original open-access article distributed under the terms of the Creative Commons Attribution-noncommercial 4.0 International License which permits copy and redistribution of the material just in noncommercial usages with proper citation.

### ABSTRACT

The 2019 Coronavirus disease pandemic (COVID-19) has spread to over two hundred countries worldwide, affecting > 170 million people and causing >3,500,000 deaths (May 29, 2021). Severe COVID-19 disease mostly disturbs the respiratory system, but gastrointestinal symptoms, including vomiting, nausea and diarrhea, are also present. Herein, we are reporting a COVID-19 patient with acute pancreatitis (AP) in Zanzan, Iran. . This patient showed acute pancreatitis as a COVID-19-related complication, emphasizing the importance of evaluating pancreas-specific plasma amylase levels in patients with COVID-19 and intestinal cramping.

**Keywords:** COVID-19, Pancreatitis, Iran

## Introduction

The global pandemic of Coronavirus disease-2019 (COVID-19) has reached over two hundred countries worldwide, affecting > 170 million people and causing > 3,500,000 deaths (May 29,2021) (1, 2). The severity of the illness varies from subclinical infections to the serious disease that requires hospitalization (3, 4). Severe acute respiratory syndrome coronavirus 2 (SARS-CoV-2) mostly impacts the respiratory system, but there are also gastrointestinal signs, such as vomiting, nausea, and diarrhea (5, 6). Abdominal pain is prevalent in chronically- ill cases (7, 8). Viral RNA has been detected in fecal specimens and in gastrointestinal epithelial cells, indicating a potential path of fecal-oral transmission (9, 10). The most frequent gastrointestinal source of hospitalization in the United States is severe pancreatitis (11, 12). Acute pancreatitis formation is multifactorial, involving susceptibility and related damage (13). Gallstones and alcohol consumption are the most

prevalent causes, however; virus-induced acute pancreatitis has also been identified.

## Case Report

Documents were collected from a patient admitted to the Intensive Care Unit with COVID-19 at Valiasr hospital in Zanzan province of Iran in October 2020. Acute pancreatitis was diagnosed based on the Atlanta category. Swab samples and tracheal aspirates were taken from the patient. Blood testing including C- reactive protein (CRP), creatine kinase plus myoglobin, aspartate aminotransferase (AST) alanine aminotransferase (ALT), lactate dehydrogenase (LDH), D-dimer, and creatine phosphokinase levels and also diagnostic imaging were carried out.

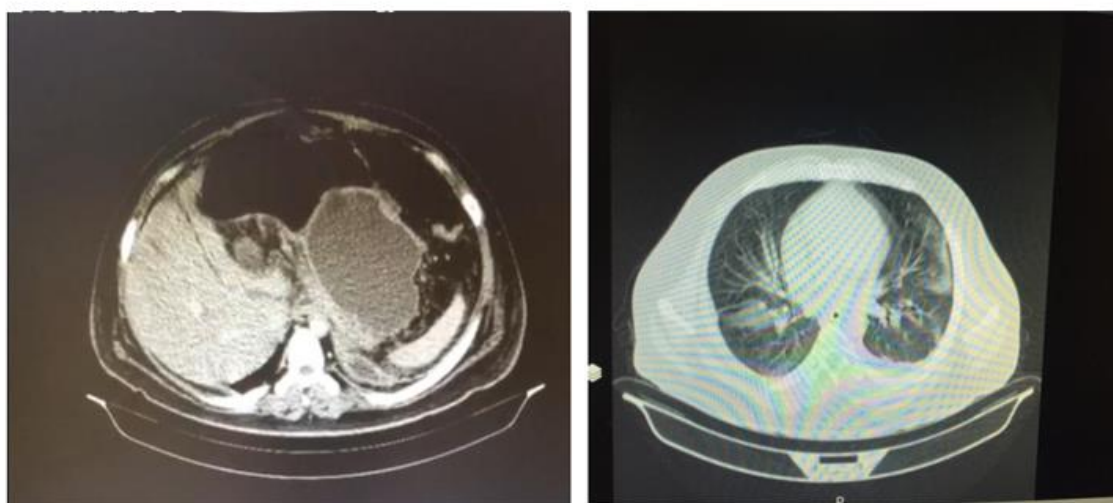
A 28- year-old obese (BMI = 42) male presented with acute abdominal pain, vomiting, weakness, nausea, decreased appetite and abdominal function for days. The case complained of severe generalized abdominal pain especially in the Right Upper Quadrant (RUQ) and epigastric region radiating to the back for 4 days. He was not taking any medicine and did not have a history of alcoholism and smoking. Physical examination upon arrival indicated blood pressure of 110/70 and temperature of 37° C.

Abdominal laboratory workup is summarized in [table 1](#). The patient's amylase was increased beyond the normal level (ULN=90). AST and ALT, triglyceride, and lipase levels were normal. Chest CT scan indicated perioral ground-glass opacity in RML, RUL LUL ([Fig a and b](#)). Plural effusion collapse, consolidation, and atelectasis in

the posterior of RLL on abdominal CT scan and severe inflammation were seen in the fat around the pancreas and the fat stranding in the kidneys especially on the left. The size of para-aortic infiltrates was normal and the pancreases showed heterogeneous density. The above symptoms can indicate necrotic pancreatitis.

**Table 1. Laboratory testing results at the time of admission**

Laboratory experiment	Result
White cell count (per mm <sup>3</sup> )	19/3
Differential Count total neutrophils (per mm <sup>3</sup> )	87/3
Total lymphocytes	10/3
Platelet Count (per mm <sup>3</sup> )	5000
Hemoglobin (g/liter)	18/3
INR	1.0
Creatinine (μmol/liter)	1/3
Albumin (g/liter)	3/4
Blood urea Nitrogen	27
Triglyceride (mg/dl)	143
LDH	2044
Amylase (U/liter)	83
Magnesium (U/liter)	2/2
Total Bilirubin (mg/dl)	0/9
Direct Bilirubin (mg/dl)	0/2
C-reactive protein (mg/liter)	5
Alanine aminotransferase (U/liter)	37
Aspartate aminotransferase (U/liter)	36



a.

b.

**Figure 1. a. Inflammation in pancreas parenchyma on CT scan, b. Pulmonary consolidation compatible with Covid-19**

The patient was identified with severe acute necrotizing pancreatitis with acute respiratory distress syndrome (ARDS). This happens when fluid builds up in the tiny, elastic air sacs (alveoli) in patients lungs. Then, the patient was admitted to the intensive care unit. He was cured symptomatically with bowel rest, intravenous crystalloid fluid resuscitation, and empirical antibiotics. The patient was RT-PCR positive for COVID-19. The patient developed acute hypoxic respiratory failure needing high flow oxygen supplementation.

## Discussion

Coronaviruses are a wide group of single-stranded RNA viruses. In humans, the virus frequently produces respiratory symptoms as well as myalgia. Our patient was PCR positive and had no other indications for pancreatitis such as gall stones, alcohol use, or medication intake. According to the COVID-19 and gastritis final symptoms evidence the patient most likely had pancreatitis in the context of corona virus. A number of etiological causes leading to acute pancreatitis have been identified. Gallstones and excessive alcohol intake are the most prevalent causes of acute pancreatitis. In 10%–20% of patients, an etiological component cannot be found. Several infectious agents, such as parasites, bacteria and viruses are recognized to infect the pancreas. Numerous gastrointestinal symptoms have been observed in COVID-19 patients. Mach *et al.*, reported a 37-year-old woman with concomitant respiratory and gastrointestinal symptoms pancreatitis in the context of COVID-19. Also, absence of additional etiologies would recommend coronavirus-induced acute pancreatitis. In another study, it was reported that COVID-19 patients showed the pancreatic injury known by any abnormalities in amylase / lipase in less than 20% of cases (1). Some evidence has confirmed that COVID-19 could be related with gastrointestinal symptoms including abdominal pain (2-4) with identification of viral RNA in gastrointestinal tract (5-9).

Many variables such as pancreatic autodigestion, system complement, and enzyme activation, could induce acute pancreatitis activation. The hypothesis of microcirculation disruption, showed elevated leukocytes and pancreatic acinar cell necrosis and apoptosis (14). Viral pancreatitis occurs potentially due to the overt degradation via inflammatory and edema of pancreatic acinar cells. Additionally, damage by the virus to the pancreatic acinar cells may result in elevated intracellular enzyme or induce an apoptosis phase (14). COVID-19 pathogenesis is suspected to be regulated by the target cells' angiotensin-converting enzyme-2 (ACE-2) receptor, which is strongly expressed in the pancreatic cells (15). Thus, the cases presented highlight the significance of amylase or lipase measurement in patients with SARS-CoV-2 infection, particularly if patients suffer stomach pain.

## Conclusion

None.

## Acknowledgments

None.

## Conflict of Interest

None.

## References

1. Chinazzi M, Davis JT, Ajelli M, *et al.* The effect of travel restrictions on the spread of the 2019 novel coronavirus (COVID-19) outbreak. *Science*. 2020;368(6489):395-400. [PMID] [PMCID] [DOI:10.1126/science.aba9757]
2. Baud D, Qi X, Nielsen-Saines K, Musso D, Pomar L, Favre G. Real estimates of mortality following COVID-19 infection. *Lancet Infect Dis*. 2020;20(7):773 [DOI:10.1016/S1473-3099(20)30195-X]
3. Zhu J, Ji P, Pang J, *et al.* Clinical characteristics of 3,062 COVID-19 patients: a meta-analysis. *J Med Virol*. 2020; 92(10):1902-14. [DOI:10.1002/jmv.25884] [PMID] [PMCID]
4. Asghari A, Naseri M, Safari H, Saboory E, Parsamanesh N. The novel insight of SARS-CoV-2 molecular biology and pathogenesis and therapeutic options. *DNA Cell Biol*. 2020; 39(10): 1741-53 [DOI:10.1089/dna.2020.5703] [PMID]
5. Nobel Y, Phipps M, Zucker J. Gastrointestinal symptoms and COVID-19: case-control study from the United States. *Gastroenterology*. 2021; 159(1): 373-375.e2 [PMID] [PMCID] [DOI:10.1053/j.gastro.2020.04.017]
6. Parsamanesh N, Pezeshgi A, Hemmati M, Jameshorani M, Saboory E. Neurological manifestations of coronavirus infections: role of angiotensin-converting enzyme 2 in COVID-19. *Int J Neurosci*. 2020:1-11. [DOI:10.1080/00207454.2020.1849193] [PMID]
7. Zhang Z, Zhang L, Zha D, Hu C, Wu X. Clinical characteristics and risks of China's 2019 novel coronavirus patients with AKI: a systematic review and meta-analysis. *Renal Failure*. 2020; 42(1):926-31. [DOI:10.1080/0886022X.2020.1812401]
8. Xiao F, Tang M, Zheng X, Liu Y, Li X, Shan H. Evidence for gastrointestinal infection of SARS-CoV-2. *Gastroenterol*. 2020;158(6):1831-3. e3. [DOI:10.1053/j.gastro.2020.02.055] [PMID] [PMCID]
9. Cheung KS, Hung IF, Chan PP, *et al.* Gastrointestinal manifestations of SARS-CoV-2

- infection and virus load in fecal samples from the Hong Kong cohort and systematic review and meta-analysis. *Gastroenterol.* 2020; 159(1):81-95 [[DOI:10.1053/j.gastro.2020.03.065](https://doi.org/10.1053/j.gastro.2020.03.065)] [[PMID](#)] [[PMCID](#)]
10. D'Amico F, Baumgart DC, Danese S, Peyrin-Biroulet L. Diarrhea during COVID-19 infection: pathogenesis, epidemiology, prevention and management. *Clin Gastroenterol Hepatol.* 2020; 18(8):1663-72. [[DOI:10.1016/j.cgh.2020.04.001](https://doi.org/10.1016/j.cgh.2020.04.001)] [[PMID](#)] [[PMCID](#)]
  11. Peery AF, Dellon ES, Lund J, et al. Burden of gastrointestinal disease in the United States: 2012 update. *Gastroenterol.* 2012;143(5):1179-87. e3. [[DOI:10.1053/j.gastro.2012.08.002](https://doi.org/10.1053/j.gastro.2012.08.002)] [[PMID](#)] [[PMCID](#)]
  12. Mohamadian M, Chiti H, Shoghli A, Biglari S, Parsamanesh N, Esmacilzadeh A. COVID-19; Virology, Biology and Novel Laboratory Diagnosis. *J Gene Medicine.* 2020:e3303. [[DOI:10.1002/jgm.3303](https://doi.org/10.1002/jgm.3303)] [[PMID](#)] [[PMCID](#)]
  13. Testoni PA. Acute recurrent pancreatitis: Etiopathogenesis, diagnosis and treatment. *World J Gastroenterol.* 2014;20(45):16891. [[PMID](#)] [[DOI:10.3748/wjg.v20.i45.16891](https://doi.org/10.3748/wjg.v20.i45.16891)]
  14. Hadi A, Werge MP, Kristiansen KT, et al. Coronavirus disease-19 (COVID-19) associated with severe acute pancreatitis: Case report on three family members. *Pancreatol.* 2020; 20(4):665-67 [[DOI:10.1016/j.pan.2020.04.021](https://doi.org/10.1016/j.pan.2020.04.021)] [[PMID](#)] [[PMCID](#)]
  15. Yang JK, Lin SS, Ji XJ, Guo LM. Binding of SARS coronavirus to its receptor damages islets and causes acute diabetes. *Acta diabetologica.* 2010;47(3):193-9. [[DOI:10.1007/s00592-009-0109-4](https://doi.org/10.1007/s00592-009-0109-4)] [[PMID](#)] [[PMCID](#)]

#### How to Cite This Article:

Jameshorani M, Meydanloo M, Jafari S, Mansouri Hashchin S, Jafari M, Parsamanesh N. Coronavirus Disease-19 (COVID-19) Presenting with Severe Acute Pancreatitis: A Case Report from Iran, *J Adv Med Biomed Res.* 2022; 30(140): 295-298.

#### Download citation:

[BibTeX](#) | [RIS](#) | [EndNote](#) | [Medlars](#) | [ProCite](#) | [Reference Manager](#) | [RefWorks](#)

#### Send citation to:

 [Mendeley](#)  [Zotero](#)  [RefWorks](#) [RefWorks](#)