

Metastatic Bilateral Ovarian High Grade Serous Carcinoma to the Appendix: A Diagnosis Pitfall

Fatemeh Samiee-Rad* 

Dept. of Pathobiology, Clinical Research Development Unit, Kosar Hospital, Qazvin University of Medical Sciences, Qazvin, Iran

Article Info

Received: 2021/01/29; Accepted: 2022/07/27; Published Online: 08 Aug 2022;

 [10.30699/jambs.30.142.468](https://doi.org/10.30699/jambs.30.142.468)

Use your device to scan and read the article online



Corresponding Information:

Fatemeh Samiee-Rad,
Dept. of Pathobiology, Clinical Research Development Unit, Kosar Hospital, Qazvin University of Medical Sciences, Qazvin, Iran
E-Mail: fsamieerad@gmail.com



Copyright © 2022, This is an original open-access article distributed under the terms of the Creative Commons Attribution-noncommercial 4.0 International License which permits copy and redistribution of the material just in noncommercial usages with proper citation.

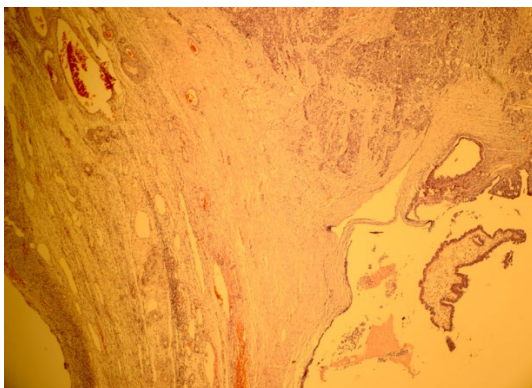
Dear Editor

Secondary appendiceal neoplasms are extremely rare conditions accounting for about 0.1% of total appendix malignancies (1). The clinical presentation is most prevalent as acute appendicitis and incidental finding can occur during other investigations (2). Ovarian cancer prognosis, especially dissemination form remains poor with a high mortality rate (3).

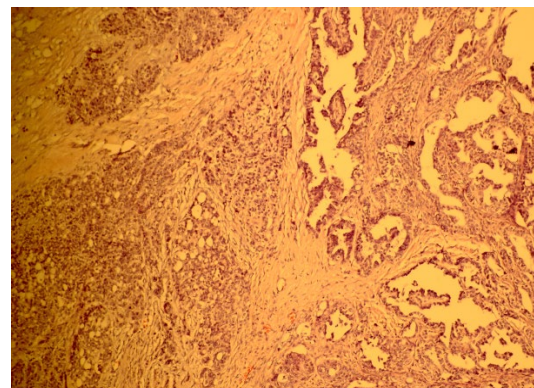
Synchronized evidence of bilateral ovarian masses with an asymptomatic incidental appendiceal solitary mass is an unusual event during operation. The results of Babaier et al., and Kumar demonstrated, that the main differential diagnosis is metastatic mucinous adenocarcinoma of ovary to appendix versus metastatic mucinous neoplasm of appendix in both sides of ovaries (4,5). Yoon et al., study findings showed that metastasis of bilateral ovarian high grade serous carcinoma to the appendix is an extremely rare event (6).

A 43-year-old woman presented to our hospital with a several- month history of menstrual irregularity. She underwent physical, imaging, and laboratory evaluations. Finally surgical interventions were made. Imaging studies, including ultrasound and CT scan findings showed bilateral ovarian solid cystic masses and mild peritoneal effusion. CA 125 had increased mildly. (60 U/mL). During surgery, on palpation, an incidental small-sized appendiceal lesion was found. The patient underwent total abdominal hysterectomy, bilateral salpingo oophorectomy, omentectomy, pelvic lymph nodes dissection and appendectomy.

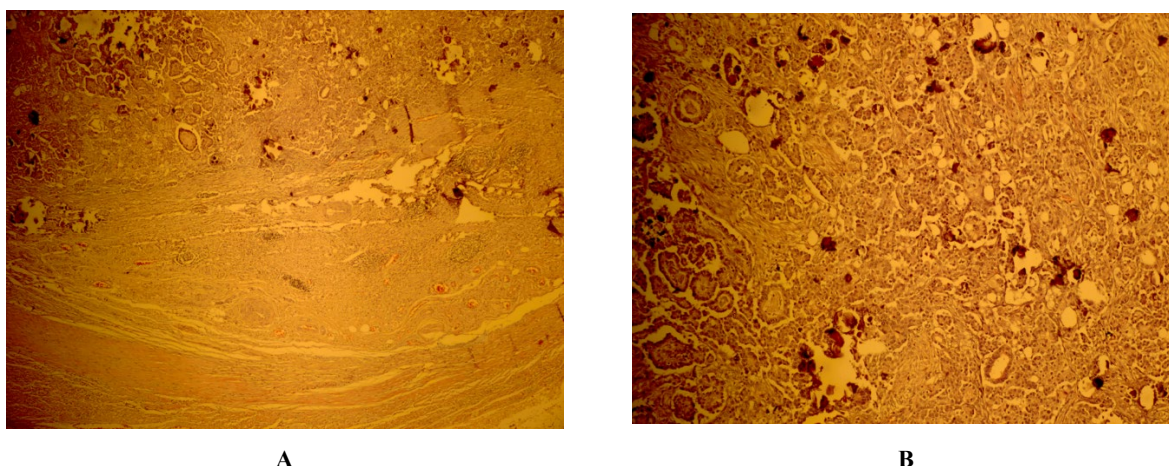
Histomorphologic results of ovaries and appendix showed malignant infiltrative neoplasm populated by pleomorphic tumoral cells in solid, cribriform, papillary pattern. The atypical mitosis and necrosis were seen. The psammoma bodies, were exclusively seen in appendiceal sections (Figures 1 and 2 A,B).



A



B

Figure 1. A,B. Histomorphologic results of ovarian high grade serous carcinoma.. Hematoxylin and eosin staining, X10 & 400.**Figure 2. A,B. Histomorphologic results of metastatic high grade serous carcinoma of appendix with psammoma bodies. Hematoxylin and eosin staining, X10 & 400.**

Final diagnosis, according to histopathological and immunohistochemical findings (expressions of CK7, Pax8, WT1 were positive and CK20, TTF1, CDX2, Napsin, GATA, CEA negative) was metastatic bilateral ovarian high grade serous carcinoma of the appendix. All pelvic regional lymph nodes were free from tumor. Pelvic peritoneum was involved by tumoral seeding.

There are three mechanisms for metastatic appendiceal involvement, including angiolymphatic invasion, peritoneal seeding, and transcoelomic and direct extension (6, 7). Most important pathways in the present case were angiolymphatic invasion and peritoneal seeding. However, transcoelomic spread was not the main mechanism, because muscularis propria of the appendix was invaded by metastatic tumor, but serosa layer was intact.

Accurate detection of primary or metastatic ovarian cancer, especially with bilateral involvement is crucial, because therapeutic interventions and prognosis are variable. For a definite diagnosis, immunohistochemical studies are highly mandatory. The important markers for this purpose are cytokeratin 7, PAX 8, and Wilms Tumor 1. These tumor markers may be useful for final diagnosis because their tumoral tissue expression is not 100% (8). Therefore, using these markers along with histopathology findings, can definitely be helpful.

Conflict of Interest

Authors declared no conflict of interest.

References

1. Kinnear N, Heijkoop B, Bramwell E, et al. Communication and management of incidental pathology in 1,214 consecutive appendectomies; a cohort study. *Int J Surg.* 2019;72:185-91. [DOI:10.1016/j.ijssu.2019.10.025] [PMID]
2. Brunner M, Lapins P, Langheinrich M, et al. Risk factors for appendiceal neoplasm and malignancy among patients with acute appendicitis. *Int J Colorectal Dis.* 2020;35(1):157-63. [DOI:10.1007/s00384-019-03453-5] [PMID]
3. Della Corte L, Giampaolino P, Fabozzi A. Breast metastasis two years after pelvic surgery and adjuvant chemotherapy for serous ovarian cancer. *Gynecol Endocrinol.* 2019;35(3):211-3. [DOI:10.1080/09513590.2018.1521795] [PMID]
4. Babaier A, Ghatage P. Mucinous cancer of the ovary: overview and current status. *Diagnostics.* 2020;10(1):52. [PMCID] [DOI:10.3390/diagnostics10010052] [PMID]
5. Kumar T, Khanna P, Nigam JS, Singh A, Agrawal N. Mucinous appendiceal tumor presenting as bilateral adnexal mass. *J Gastrointest Canc.* 2020;52:347-50. [DOI:10.1007/s12029-020-00453-5] [PMID]
6. Yoon WJ, Yoon YB, Kim YJ, Ryu JK, Kim YT. Secondary appendiceal tumors: a review of 139 cases. *Gut Liver.* 2010;4(3):351. [PMCID] [DOI:10.5009/gnl.2010.4.3.351] [PMID]
7. Simpson GS, Mahapatra SR, Evans J. Incidental complete excision of appendiceal gastric cancer metastasis. *Int J Surg Case Rep.* 2013;2013(10):rjt080. [DOI:10.1093/ijscr/rjt080] [PMID] [PMCID]
8. Ghelichkhani M, Naffisi N, Meydansar FG, Rahimi Z, Haghighikhan M, Sadeghi L. Ovarian cancer metastatic to breast and axilla: A case report. *Arch Breast Can.* 2020;88-92. [DOI:10.32768/abc.20207288-92]

How to Cite This Article:

Samice-Rad F. Metastatic Bilateral Ovarian High Grade Serous Carcinoma to the Appendix: A Diagnosis Pitfall. J Adv Med Biomed Res. 2022; 30 (142): 468-70.

Download citation:

[BibTeX](#) | [RIS](#) | [EndNote](#) | [Medlars](#) | [ProCite](#) | [Reference Manager](#) | [RefWorks](#)

Send citation to:

 [Mendeley](#)  [Zotero](#)  [RefWorks](#) [RefWorks](#)