Journal of Advances in Medical and Biomedical Research | ISSN:2676-6264

Successful Treatment of Rhinocerebral Mucormycosis in A Diabetic Patient following Cerebrovascular Accident: A Case Report

Samira Akbarieh [1], Behnam Sajedi [1], Narges Soozangar [1*], Pourya Gholizadeh [1], Behnam Mohammadi-Ghalehbin [1]

1. *Zoonoses Research Center, Ardabil University of Medical Sciences, Ardabil, Iran*

Article Info

Received: 2026/05/01;

Accepted: 2026/06/28;

Published Online: 2026/10/18;

***Corresponding author:**

Narges Soozangar,

Zoonoses Research Center, Ardabil University of Medical Sciences, Ardabil, Iran

Email: soozangar.narges@gmail.com

How to Cite This Article:

Akbarieh S, Sajedi B, Soozangar N, Gholizadeh P, Mohammadi-Ghalehbin B. Successful Treatment of Rhinocerebral Mucormycosis in A Diabetic Patient following Cerebrovascular Accident: A Case Report. J Adv Med Biomed Res 2026; 34(5):522-527.

ABSTRACT

Mucormycosis is an aggressive fungal infection that can lead to fatal complications in patients with underlying compromising conditions if not promptly and vigorously managed. A 65-year-old female from Ardabil, Iran, with Type 2 diabetes mellitus (DM), presented with left-sided hemiplegia and hemiparesis. Within five days of admission, she developed pain, left-sided facial swelling, fever, and chills. She had also been undergoing treatment for brucellosis for the past two months. Physical examination revealed a necrotic lesion on the hard palate and upper lip. Laboratory tests were performed, and subsequent nasal endoscopy confirmed the presence of mucormycosis hyphae. A sinus MRI indicated invasive fungal sinusitis and mastoiditis. Pathology of the excised palatal lesion confirmed mucormycosis. The patient was treated with amphotericin B and posaconazole, alongside management of her comorbidities. Surgical interventions included removal of the maxillary sinus wall and nasal cavity exploration. Following a six-month course of maintenance therapy, the patient achieved a full recovery.

Keywords: *Rhinocerebral, mucormycosis, fungal infection, diabetes mellitus*

Copyright © 2026, This is an original open-access article distributed under the terms of the Creative Commons Attribution-noncommercial 4.0 International License which permits copy and redistribution of the material just in noncommercial usages with proper citation.

1. Introduction

Mucormycosis is an opportunistic fungal infection that usually occurs in individuals with predisposing conditions, such as diabetes mellitus, hematologic malignancies, immunosuppressive therapy, iron overload, organ transplantation, and renal failure (1). The infection may affect the pulmonary, soft tissue, and skin tissues, as well as the rhinocerebral, gastrointestinal, and central nervous systems. Clinical manifestations can depend on the anatomic site; the most frequent site of involvement is the sinuses (a condition known as the rhinocerebral form) (2, 3). This form of mucormycosis presents with nonspecific symptoms and signs, such as headache and fever, or more specifically, with black necrotic eschar on the palatine or nasal mucosa, brain involvement, and orbital invasion (2). Early diagnosis of this fatal infection, followed by immediate surgical and medical interventions, can help prevent its progression and reduce the high morbidity and mortality associated with this disease (4). Here, we present a case of rhinocerebral mucormycosis in a diabetic patient with a timely diagnosis and successful treatment.

2. Case Report

A 65-year-old female from Ardabil, Iran, with a 10-year history of Type 2 diabetes mellitus and a recent 10-day history of a cerebrovascular accident (CVA), presented to the emergency department with a chief complaint of left-sided hemiplegia and hemiparesis. Additionally, she had been undergoing treatment for brucellosis for the past two months.

Five days after admission, the patient developed progressive pain, left-sided facial swelling (particularly periorbital), fever, and chills. Physical examination revealed a focal yellow necrotic lesion on the hard palate and upper lip. Laboratory tests performed upon admission and after treatment are summarized in Table 1.

Table 1. The laboratory tests before and after treatment.

Laboratory tests	Before treatment	After treatment	Normal range
WBC (cu/mm)	30,800	4,900	4-10×10^3
RBC (million/mm$^{3)}$	3.09	3.24	4.2-5.4
Hb (g/dl)	8.7	8.9	12-16
Hct (%)	27.4	27.8	36-46
MCV (fL)	89	86	80-96
MCH (Pgr)	28	27	26-32
MCHC (g/dl)	32	32	26-36
PLT (µl)	327000	199000	150000-450000
ESR (mm/hr)	44	41	<20
PT (sec) (activity 96%)	13.6	13.4	
PTT (sec)	30	35	30-35
INR	1.2	1.2	1-1.4
CRP	20	Negative	<10.0 mg/L
Fasting blood sugar (mg/dl)	352	120	70-130 mg/dL
Urea mg/dL	51	25	15-45
Creatinine, (mg/dl)	1.6	1.17	0.5-1.4
AST (IU/L)	40	35	5-40
ALT (IU/L)	63	10	5-40
ALP (IU/L)	678	316	64-306
Total bilirubin (mg/dl)	1.24	1.1	0.2-1.2
Direct bilirubin (mg/dl)	0.94	0.46	0-0.4
Sodium (mEq/L)	143	140	132-145
Potassium (mEq/L)	4	4/2	3.7-5.5
Ca (mg/dl)	8.87	8.34	8.2-10.7
Phosporus (mg/dl)	3.87	3.86	2.5-5
Albumin (g/dl)	2.99	3	3.5-5.5
HbA1C	9.5	9.5	4-5.7

Note: WBC; White Blood Cell Count, RBC; Red Blood Cell Count, Hb; Hemoglobin, Hct; Hematocrit, MCV; Mean corpuscular volume, MCH; Mean Corpuscular Hemoglobin, MCHC; Mean Corpuscular Hemoglobin Concentration, PLT; Platelet Count, ESR; Erythrocyte Sedimentation Rate, PT; Prothrombin Time, PTT; Partial-thromboplastin time, INR; International normalized ratio, CRP; C-reactive protein, AST; Aspartate aminotransferase, ALT; Alanine Aminotransferase, ALP; Alkaline phosphatase.

The physical examination revealed a focal yellow necrotic lesion on the hard palate and upper lip. The laboratory tests performed during admission and after treatment are listed in Table 1. Subsequently, the patient underwent diagnostic nasal endoscopy. Direct mycological examination revealed broad, aseptate mucormycosis hyphae branching at right angles (Figure 1). Fungal cultures yielded grayish-brown colonies with a cottony texture, identifying *Zygomycetes* species based on macroscopic and microscopic features (Figure 2).

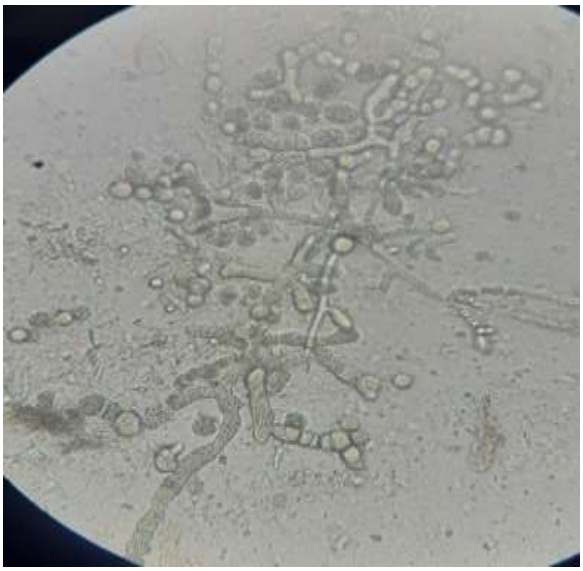

Figure 1. Direct mycological smear presenting broad, aseptate right-angled branching mucormycosis hyphae. (**Prepared by Authors, 2026**).



Figure 2. Mycological culture shows grayish-dark brown colonies with a cottony texture, in which Zygomycetes spp. were identified employing both macroscopic and microscopic features.(**Prepared by Authors, 2026**).

Paranasal sinus MRI revealed fluid accumulation and mucosal thickening in all paranasal sinuses—more prominent on the left side—as well as in the mastoid air cells. Retroantral fat stranding and signal changes were observed, reflecting the extension of infection and inflammatory changes from the left maxillary sinus. Bony erosions were identified at the medial and posterolateral walls of the left maxillary sinus, alongside a suspicious bony erosion at the left cribriform plate. These findings strongly favored invasive fungal sinusitis and mastoiditis. A subsequent brain MRI yielded normal results.

Histopathological examination of the excised palatal lesion demonstrated fibroadipose tissue with marked inflammation, foci of necrosis, and hemorrhage, lined by respiratory-type epithelium. Scattered, broad, pauci-septate, ribbon-like hyphae with irregular branching were observed, consistent with a fungal infection (*Zygomycetes*). These histopathological characteristics confirmed the diagnosis of mucormycosis.

Given the patient's clinical presentation and the high suspicion of mucormycosis, she was initiated on a regimen of amphotericin B (5 mg/kg, totaling 300 mg) and posaconazole (300 mg) daily for one month upon admission. Concurrently, her underlying comorbidities were addressed. Due to sepsis in the context of diabetic ketoacidosis (DKA), as well as the management of sinusitis and otitis, empiric antibiotic therapy with meropenem and vancomycin was also administered. To prevent enucleation, the patient received intraocular injections of amphotericin B and voriconazole during the initial month of hospitalization.

Renal function was closely monitored via regular laboratory testing to detect potential nephrotoxicity secondary to amphotericin B administration, and dosages were adjusted accordingly to ensure patient safety.

Based on the patient's clinical condition and high suspicion of mucormycosis, treatment was initiated promptly upon admission with intravenous amphotericin B (5 mg/kg, total 300 mg daily) and posaconazole (300 mg daily) for one month. During the treatment period, underlying predisposing factors and comorbidities were managed concurrently. Additionally, meropenem and vancomycin were prescribed to manage sepsis in the setting of diabetic ketoacidosis (DKA), alongside secondary sinusitis and otitis. During the first month of hospitalization, surgical enucleation was successfully avoided following local interventions involving intraocular injections of amphotericin B and voriconazole. Routine laboratory monitoring was performed to detect amphotericin B-induced nephrotoxicity, and dosages were adjusted as needed.

In light of the endoscopic and imaging findings, the patient underwent serial surgical debridements. Nasal endoscopies were conducted to remove crusts and inspect the nasal and sinus cavities. During surgery, the entire inner wall of the maxillary sinus and the anterior and posterior ethmoid air cells were removed down to healthy tissue (ethmoidectomy). The sphenoid sinus was also opened, and nasal polyps were excised to facilitate the drainage of fungal elements. In a subsequent fourth operation, resection of the involved palate was performed by a maxillofacial surgeon, followed by the removal of the cartilaginous nasal septum and the inferior and middle turbinates. The patient also underwent postoperative nasal endoscopies under intravenous sedation to clear crusting

and check the cavities for signs of recurrence. Posaconazole was initially continued as salvage therapy at 300 mg once daily for one month; however, due to regional drug shortages, maintenance therapy was subsequently transitioned to an alternative oral regimen of itraconazole (200 mg every 12 hours). Later in the clinical course, the patient required prolonged intubation for two weeks due to secondary aspiration pneumonia, making extubation a challenging process. Following the successful completion of a six-month course of antifungal maintenance therapy, the patient achieved a full recovery.

3. Discussion

Mucormycosis comprises a group of rapidly progressive and frequently fatal opportunistic infections caused by fungi belonging to the order Mucorales and the class Zygomycetes (5, 6). It is recognized as the third most common opportunistic fungal infection, following candidiasis and aspergillosis (7). Typically, these microorganisms inhabit soil and various decaying organic materials, releasing numerous spores into the environment. The primary route of human infection is through the inhalation of these spores. While phagocytic clearance effectively prevents pathogenicity in immunocompetent individuals (8). those with underlying immunosuppression or chronic disease are at significant risk for severe pulmonary, rhinocerebral, cutaneous, and gastrointestinal infections (9).

Established risk factors include organ transplantation, lymphoma, iron overload, and long-term immunosuppressive or corticosteroid therapy; among these, diabetes mellitus (DM) remains the most prevalent risk factor (10, 11). The management of mucormycosis in diabetic patients is exceptionally challenging, as hyperglycemia and metabolic acidosis create a highly permissive environment for fungal proliferation. Acidosis, in particular, impairs the phagocytic capacity of immune cells to eliminate spores through both non-oxidative and oxidative burst mechanisms (12). Rhinocerebral mucormycosis is the most frequent clinical manifestation of this infection (13). Initial symptoms often include headache, fever, facial swelling, proptosis, and localized pain. Once the fungus establishes a foothold within the nasal mucosa, it can rapidly extend into adjacent anatomical structures. Mucormycosis exhibits a high propensity for invading the orbital and paranasal sinuses. Extension into the retro-orbital region can result in damage to the posterior cranial nerves, manifesting clinically as impaired extraocular movements, mydriasis (dilated pupils), and vision loss (12). In the present case, the patient's clinical course began with a cerebrovascular accident (CVA), likely precipitated by the microvascular and macrovascular complications of uncontrolled diabetes mellitus and diabetic ketoacidosis (DKA). This was subsequently followed by the development of rhinocerebral mucormycosis. Neurological damage in mucormycosis is multifaceted, primarily driven by the direct angioinvasive spread of the pathogen. The fungus causes vascular occlusion, dissection, or narrowing of the arterial walls, which can trigger either hemorrhagic or ischemic strokes.

While cerebral complications are frequently documented in the literature, the management of stroke within the context of an active mucormycosis infection is of paramount importance. Rapid identification of the pathogen and the immediate initiation of targeted, aggressive antifungal therapy are essential to improve clinical outcomes. For patients presenting with cerebral involvement, such as mucormycosis-induced stroke, timely diagnosis and multidisciplinary intervention—including optimized antifungal regimens and surgical debridement—are critical for survival. Additionally, prolonged antibiotic therapy is a recognized risk factor for the development of mucormycosis (14).

In the present case, the patient's recent diagnosis of brucellosis necessitated a two-month course of antibiotic treatment, potentially predisposing him to this opportunistic fungal infection. While numerous reports have documented strokes associated with rhino-orbito-cerebral mucormycosis (15, 16). This case is unique, as it is the first documented instance involving a patient undergoing treatment for brucellosis who also presented with a preceding cerebrovascular accident (CVA). Brucellosis can induce significant systemic immunosuppression, rendering individuals more susceptible to opportunistic pathogens. The chronic inflammatory state and the systemic burden of brucellosis may further compromise host defenses, thereby enhancing the risk of secondary fungal infections(17). Furthermore, emerging evidence suggests that a recent stroke may impair systemic immune responses, thereby increasing susceptibility to infection (18). Consequently, both brucellosis and a recent CVA may act as synergistic risk factors for the development of mucormycosis due to their respective roles in immunosuppression. Given these associations, patients with brucellosis or recent cerebrovascular accidents should be closely monitored for symptoms indicative of mucormycosis, such as facial pain, nasal congestion, or other signs of systemic fungal involvement. The prognosis for mucormycosis varies significantly based on the extent of the infection; while survival rates for isolated invasive sinus disease range from 50% to 80%, the case fatality rate can exceed 80% once the infection involves the central nervous system (15). Prognosis deteriorates further if the carotid artery becomes involved. For instance, a study by Thajeb et al. reported on six patients with rhino-orbito-cerebral mucormycosis and large vessel involvement, all of whom succumbed to the disease (16). In our case, the successful recovery was predicated on rapid diagnosis and the timely initiation of intensive combination antifungal therapies. Furthermore, a multi-stage surgical approach—encompassing the sinuses, palate, and orbital regions—was vital in preventing fatal complications and ensuring a favorable outcome. Five days after admission, the patient developed progressive symptoms, including left-sided facial pain, periorbital swelling, fever, and chills. Physical examination further revealed a focal yellow necrotic lesion on the hard palate and upper lip. In this diabetic patient with a high suspicion of an invasive fungal infection, treatment was initiated immediately based on clinical presentation and laboratory findings.

Mucormycosis is characterized by extensive angioinvasion, leading to vascular thrombosis and subsequent tissue necrosis. This pathological process prevents the adequate delivery of host leukocytes and systemic antifungal agents to the foci of infection, rendering the fungus exceptionally difficult to eradicate (19). Consequently, the management of mucormycosis necessitates a combined protocol of aggressive antifungal therapy and targeted surgical debridement tailored to the affected anatomical sites and the severity of involvement (20). Systemic antifungal therapy with intravenous amphotericin B must be commenced without delay. Liposomal amphotericin B is generally preferred over conventional formulations due to its superior tolerability and more favorable side-effect profile in systemically compromised patients. Although lipid complex amphotericin B is often more accessible and cost-effective, liposomal formulations offer reduced nephrotoxicity (19). Furthermore, several studies support the use of posaconazole as an effective second-line agent for salvage therapy in refractory cases (21, 22). In the present case, liposomal amphotericin B and posaconazole were administered intravenously, and serial surgical debridements were promptly performed based on endoscopic and imaging findings to remove necrotic debris and fungal crusts.

Ultimately, this case underscores the critical importance of a comprehensive diagnostic approach—integrating past medical history, thorough clinical examinations, advanced imaging, smear cytology, and microbial culture—to confirm mucormycosis and ensure the timely initiation of appropriate antifungal therapy and surgical intervention.

4. Conclusion

Mucormycosis is an exceptionally aggressive fungal infection that carries a high risk of fatality in immunocompromised patients unless managed with prompt and vigorous intervention. In this case, successful therapeutic outcomes were achieved through a multifaceted approach, beginning with powered nasal endoscopic debridement, which proved both feasible and efficient for achieving excellent local control and reducing morbidity. Central to this success was an optimized combination antifungal therapy, utilizing specific dosages and durations that were tailored beyond standard empiric protocols. Furthermore, a novel multi-stage surgical strategy was employed to mitigate the risk of cerebrospinal fluid (CSF) leakage, while targeted intraocular injections and optimized topical treatments were implemented to rapidly control periocular discharge and infection. Crucially, the stabilization of diabetic ketoacidosis (DKA) and the intensive management of uncontrolled diabetes provided the necessary physiological foundation for recovery. This success was further sustained by rigorous post-discharge follow-up and the meticulous administration of maintenance oral therapy, which prevented disease recurrence and ensured the complete resolution of clinical, laboratory, and radiological symptoms. Ultimately, the complex coordination of these multidisciplinary diagnostic and therapeutic strategies proved essential in overcoming severe complications and achieving full patient recovery.

5. Declarations

5.1 Acknowledgments

The authors would like to sincerely thank Ardabil University of Medical Sciences.

5.2 Ethical Considerations

This study was approved by the Ethics Committee of Ardabil University of Medical Sciences (Ethics Code: IR.ARUMS.REC.1402.169).

5.3 Authors' Contributions

SA and NS were responsible for the study proposal, information acquisition, statistical analyses, and manuscript writing; NS and PG contributed to data acquisition and manuscript preparation; and NS and BMG made considerable contributions to the idea or design of the study and English correction.

5.4 Conflict of Interest

The authors declare that they have no conflict of interest

5.5 Fund or Financial Support

This research received no specific grant from funding agencies in the public, commercial, or not-for-profit sectors.

5.6 Using Artificial Intelligence Tools (AI Tools)

The authors did not utilize AI Tools.

References

1. Afroze SN, Korlepara R, Rao GV, Madala J. Mucormycosis in a diabetic patient: a case report with an insight into its pathophysiology. Contem Clin Dentist. 2017;8:662-6. [DOI:10.4103/ccd.ccd_558_17] [PMID] [PMCID]

2. Reid G, Lynch III JP, Fishbein MC, Clark NM. Mucormycosis. Seminars in respiratory and critical care medicine: Thieme Medical Publishers; 2020. 99-114. [DOI:10.1055/s-0039-3401992] [PMID]

3. Davis K, Almog R, Peleg Y, Spiegelman L. A case report of invasive mucormycosis in a COVID-19 positive and newly-diagnosed diabetic patient. J Educ Teach Emerg Med. 2023;8:V10.

4. Bakathir AA. Mucormycosis of the jaw after dental extractions: two case reports. Sultan Qaboos Univ Med J. 2006;6:77. [DOI:10.18295/2075-0528.2630] [PMID] [PMCID]

5. Safdar A. Principles and practice of transplant infectious diseases: Springer; 2019. [DOI:10.1007/978-1-4939-9034-4]

6. Mekki SO, Hassan AA, Falemban A, Alkotani N, Alsharif SM, Haron A, et al. Pulmonary mucormycosis: A case report of a rare infection with potential diagnostic problems. Case Rep Pathol. 2020;2020:5845394. [DOI:10.1155/2020/5845394] [PMID] [PMCID]

7. Rajendra Santosh AB, Muddana K, Bakki SR. Fungal infections of oral cavity: diagnosis, management, and association with COVID-19. SN Compr Clin Med. 2021;3:1373-84. [DOI:10.1007/s42399-021-00873-9] [PMID] [PMCID]

8. Ajeel HH. Mucormycosis: Identify symptoms, diagnosis and treatment of black fungus. Ann Romanian Soc Cell Biol. 2021;25:9182-7.

9. Richardson M. The ecology of the Zygomycetes and its impact on environmental exposure. Clin Microbiol Infect. 2009;15:2-9. [DOI:10.1111/j.1469-0691.2009.02972.x] [PMID]

10. Skiada A, Pavleas I, Drogari-Apiranthitou M. Epidemiology and diagnosis of mucormycosis: an update. J Fungi. 2020;6:265. [DOI:10.3390/jof6040265] [PMID] [PMCID]

11. Rajashri R, Muthusekhar M, Kumar SP. Mucormycosis following tooth extraction in a diabetic patient: a case report. Cureus. 2020;12. [DOI:10.7759/cureus.9757]

12. Tran D, Schmit B. An aggressive case of mucormycosis. Cureus. 2020;12. [DOI:10.7759/cureus.9610]

13. Rammaert B, Lanternier F, Poirée S, Kania R, Lortholary O. Diabetes and mucormycosis: a complex interplay. Diabet Metabo. 2012;38:193-204. [DOI:10.1016/j.diabet.2012.01.002] [PMID]

14. Upadhayay P, Bansal K, Goyal A. Epidemiology, risk factors, diagnosis and treatment of mucormycosis (Black Fungus): A review. Curr Pharmaceut Biotechnol. 2023;24:1645-56. [DOI:10.2174/1389201024666230320111644] [PMID]

15. Yang G, Lin J, Dong X, Wang H, Liu X, An L. A case of rhinocerebral zygomycosis caused by Rhizopus arrhizus. Int J Dermatol. 2006;45:780-3. [DOI:10.1111/j.1365-4632.2006.02710.x] [PMID]

16. Thajeb P, Thajeb T, Dai D. Fatal strokes in patients with rhino-orbito-cerebral mucormycosis and associated vasculopathy. Scand J Infect Dis. 2004;36:643-8. [DOI:10.1080/00365540410020794] [PMID]

17. Guo X, Zeng H, Li M, Xiao Y, Gu G, Song Z, et al. The mechanism of chronic intracellular infection with Brucella spp. Front Cell Infect Microbiol. 2023;13:1129172. [DOI:10.3389/fcimb.2023.1129172] [PMID] [PMCID]

18. Shi K, Wood K, Shi FD, Wang X, Liu Q. Stroke-induced immunosuppression and poststroke infection. Stroke Vasc Neurol. 2018;3(1):34-41 [DOI:10.1136/svn-2017-000123] [PMID] [PMCID]

19. [19] Galletti B, Gazia F, Galletti C, Perani F, Ciodaro F, Freni F, et al. Rhinocerebral mucormycosis with dissemination to pontine area in a diabetic patient: Treatment and management. Clin Case Rep. 2019;7:1382-7. [DOI:10.1002/ccr3.2255] [PMID] [PMCID]

20. Daneste H, Ghadimi N, Mardani M, Maleki S, Anbardar MH, Sharifzadeh S. Successful management of rhinocerebral mucormycosis in a child with uncontrolled diabetes mellitus and recent blindness: A case report. J Res Dent Maxillofac Sci. 2022;7:98-103. [DOI:10.52547/jrdms.7.2.98]

21. Hibi A, Amakusa Y. Intracranial subdural abscess with polymicrobial infections due to frontal sinusitis in an adolescent: life-threatening complication of a common disease. Clin Case Rep. 2018;6:516. [DOI:10.1002/ccr3.1355] [PMID] [PMCID]

22. Kämppi A, Kämppi L, Kemppainen P, Kanerva M, Toppila J, Auranen M. Focal atrophy of the unilateral masticatory muscles caused by pure trigeminal motor neuropathy: case report. Clin Case Rep. 2018;6:939. [DOI:10.1002/ccr3.1495] [PMID] [PMCID]