


Educational view of Pathological Fracture of Femur due to Hydatid Cysts: A Case Report and Review of Literature

Ramin Farzam¹ , Mohammad Abdi² , Maryam Farhangi³ ,
Mohammad Zibaei⁴ , Hojjat Torkmandi^{5*} 

1. Dept. of Orthopedics, Faculty of Medicine, Zanjan University of Medical Sciences, Zanjan, Iran
2. Dept. of Critical Care Nursing, School of Nursing and Midwifery, Zanjan University of Medical Sciences, Zanjan, Iran
3. Mahak s' Pediatric Cancer Treatment and Research Center, Mahak Hospital, Tehran, Iran
4. Dept. of Parasitology, School of Medicine, Alborz University of Medical Sciences, Karaj, Iran
5. Dept. of Operating Room, School of Nursing and Midwifery, Zanjan University of Medical Sciences, Zanjan, Iran

Article Info

 [10.30699/jambs.30.141.374](https://doi.org/10.30699/jambs.30.141.374)

Received: 2021/02/07;
Accepted: 2021/05/16;
Published Online: 30 Jun 2022;

Use your device to scan and read the article online



Corresponding Information:
Hojjat Torkmandi,
Dept. of Operating Room, School of
Nursing and Midwifery, Zanjan
University of Medical Sciences, Zanjan,
Iran
E-Mail: Hojjat.or@gmail.com

ABSTRACT

Hydatid cysts can be caused by Echinococcus species in various tissues. Skeletal cystic lesions are very rare and may be neglected. Here, we report a case of pathologic fracture following primary hydatid cystic lesions in the proximal and femoral shaft bone. A 62-year-old man suffered a sudden fracture followed by swelling of the thigh. Intramedullary femoral fixation was made and during the surgery, numerous cystic lesions of the hydatid cysts were observed. After the surgery ultrasound and CT-Scans of the abdomen, lung, spine, and brain did not confirm any sign of mass or cyst elsewhere. The patient was followed up for one year. During this period, the union was not yet completely established and the patient was still receiving treatment. Orthopedic surgeons need to be aware of this parasitic complication in bones and joints and provide the best outcome for the patients with proper treatment. Surgery along with albendazole and/or mebendazole therapy remains the treatment of choice. For this purpose, it is recommended that attention be paid to long-term follow-up in continuous professional development courses.

Keywords: Hydatid cyst, Femoral bone, Fracture, Pathological fracture, Clinical education



Copyright © 2022. This is an original open-access article distributed under the terms of the Creative Commons Attribution-noncommercial 4.0 International License which permits copy and redistribution of the material just in noncommercial usages with proper citation.

Introduction

Echinococcus is a species of the Taeniidae family, which usually lives outside of the human body. This species has a high potential for the formation of a hydatid cyst in the human body. Humans can be infected through the accidental ingestion of eggs of Echinococcus from contaminated water or food. Hydatid cysts have been recognized as an endemic disease in many parts of the world (1,2). Hydatidosis in 59-75% of cases occur in the liver, 27% in the lung, 3% in the kidney, and 1-2% in the brain. The incidence of bone involvement is about 0.5-4% of all hydatid disease in human body and isolated cysts of the bone are very uncommon. Bone involvement is mainly secondary to the liver and kidney involvement (3). There are very few reports of primary bone involvement and femoral bone involvement by hydatid cysts. In this article, similar to our previous study with educational

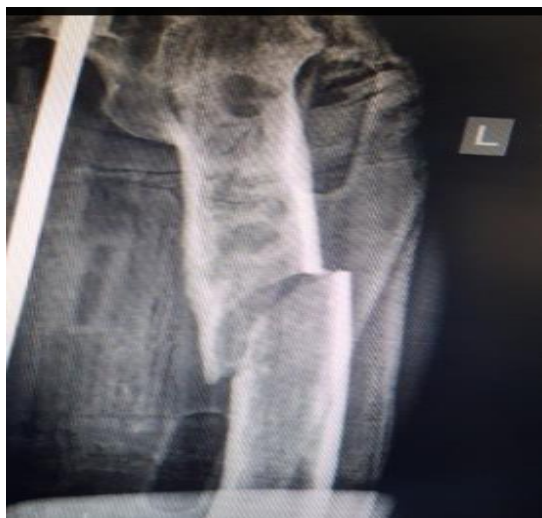view (4), we report a case of original hydatid cyst in the femur that caused pathological fracture.

Case Report

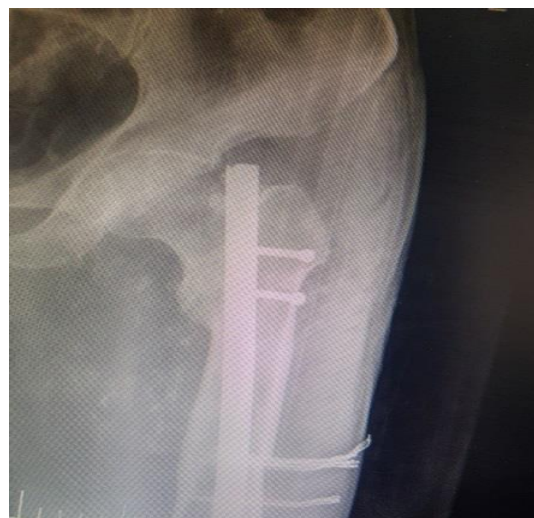A 62-year-old man was referred to the trauma center (Ayatollah Mousavi Hospital, Zanjan, Iran) with complaints of sudden femoral pain after falling. Plain radiography revealed a fracture with multiple osteolytic lesions in the proximal left femur area (Figure 1-a). The patient was a candidate for intramedullary femoral fixation (Figure 1-b). During the surgery, numerous cystic lesions of the hydatid cysts were observed (Figure 2). The surgical site and intramedullary space were irrigated with hypertonic saline. After the surgery ultrasound and CT-Scans of the abdomen, lung, spine, and brain did not

confirm any sign of mass or cyst elsewhere. All of the laboratory tests were normal. The patient was followed up for one year (8 May 2018 to 12 May 2019). During this

period, the union was not yet established and the patient was receiving treatment and follow-up.



(a)



(b)

Figure 1. a and b. Bone hydatid cyst (a) before surgery and (b) after surgery.

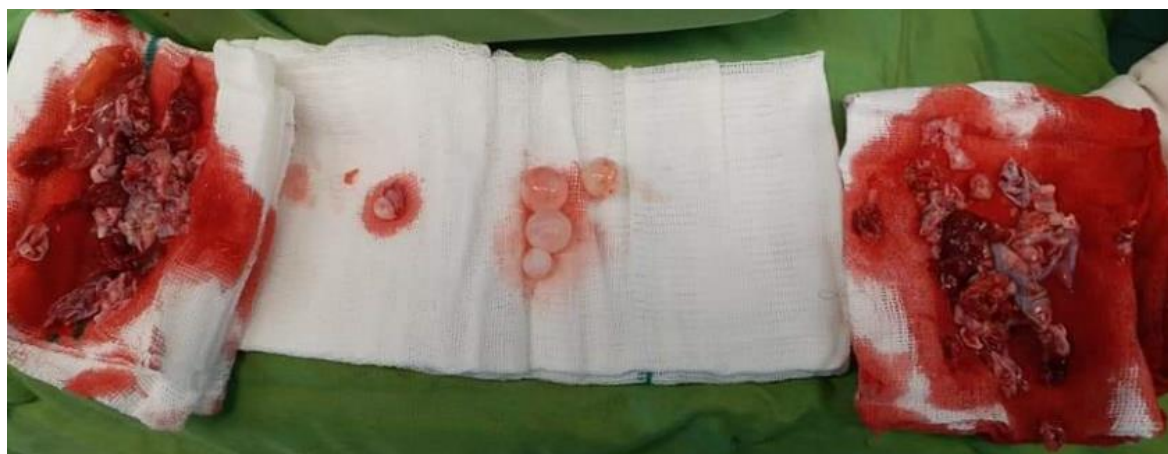

Figure 2. Photographic images of multiple hydatid cysts removed during surgery.

Discussion

In some areas of the world, there is a higher prevalence of hydatid disease than others, as shown in [Figure 3](#). Cystic echinococcosis involvement of the bone is an extremely rare condition even in endemic areas including the Middle East, Mediterranean countries, South America, North Africa, and Australia. Hydatid cysts often affect the lung and liver but rarely involve other organs such as the bone, and more than one organ has been reported to be involved in 20%-30% of cases. A very small percentage of the bone cysts may grow in the femur (2). [Table 1](#) shows the cases reported in the literature.

Many bone hydatidoses often remain asymptomatic, even in advanced age, and are diagnosed when the bones are fractured by a low-energy trauma or by pressure on adjacent components such as nerves or vessels (5). Hydatid bone disease is usually difficult to

be distinguished from chronic tuberculosis osteomyelitis, osteomyelitis, aneurysmal bone cysts (benign bone tumor with destruction), giant-cell tumors, solitary cysts, neurofibromatosis, a fibrocystic disease without direct tissue observation through surgery or histopathology. For this reason, rapid detection of hydatid cysts is very unlikely and the initial diagnosis is generally based on X-Ray graphs. Multiple clear cysts with bone expansions are shown in the X-ray images. Occasionally, bone sclerosis that produces a honeycomb-like appearance is seen. A plain X-ray image cannot make a definitive diagnosis. The addition of a CT-Scan and MRI may help to identify the area of involvement or the severity of the case (6).

Eosinophilia occurs in only 25% of cases and eosinophilia was not observed in our patient. Fine-needle aspiration (FNA) is not recommended because

of the risk of cyst spreading elsewhere (adjacent sites) or septic shock (7). The reason for the late diagnosis of hydatid cysts in the bone is the absence of symptoms due to a slight increase in the size of the cyst, in other words, as the size of the cyst increases and it grows the symptoms of the cyst appear (2). The diagnosis in our case was made when the growth of the cyst had reached such a level that it had fractured the bone by a low energy trauma.

The presence of a large number of dogs in suitable climatic and environmental conditions creates the ground for egg survival. As mentioned, our case also reported contact with several dogs in his history. The treatment of these patients differs from those of traumatic fractures of the bone. Extensive resection should be performed in the affected area (2). Despite the risk of rise of protoscoleces during surgery, it can still be considered as the best therapy modality in these patients. Several therapeutic options may be recommended as the best treatment. One of these suggestions is the use of mechanical curettage in the

involved area, the use of electric milling machines, hypertonic saline, povidone-iodine, formalin, or 0.5% silver nitrate to sterilize the involvement area. Finally, the use of autograft bone is sometimes suggested in the area (8).

Monge-Maillo et al., (2017), proposed the use of bone cement or polymethylmethacrylate (PMMA) to cover defective sites in 2017 (9). The use of intramedullary nails is another suggestion that was first proposed by Booz (1972) and colleagues (10). We followed this approach in our treatment method. In the proximal femoral bone cyst textures, valuable suggestions such as the use of custom mega prosthesis have been made. Despite all efforts, recurrence occurs in some patients. If soft tissue is broadly involved, chemotherapy is administered using albendazole or mebendazole as a standard recommendation. The WHO recommends albendazole (400 mg twice a day) for a period of 28 days, which may be repeated. It also prescribes mebendazole 50 mg/kg daily for at least three months (11).

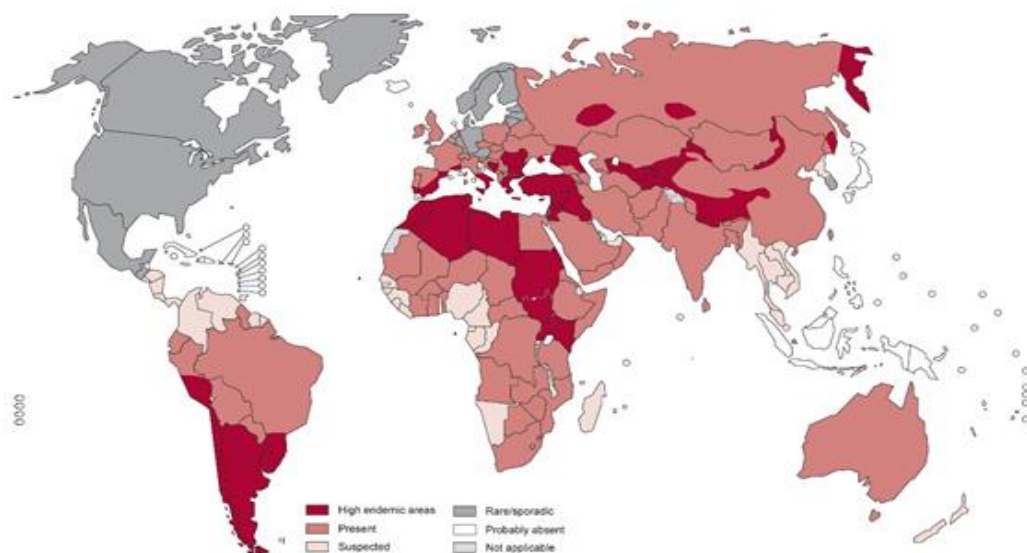


Figure 3. Distribution of *Echinococcus granulosus* and cystic echinococcosis, worldwide, 2011

Table 1. Case reports of femoral -bone Hydatidosis

Year/ Author	Age(year)/sex	Site/site	Follow-up	Treatment	Outcome
1997/Belzunegui (12)	54(F)	Femur prox	12 y	surgery + mebendazole+ albendazole	Bone Unione
2007/Mattern ([1)	62	femoral shaft		Surgery+ cement+ albendazole	Reported still undertreatment
2002/ Natarajan (13)	47	distal &prox	5y	wide resection and custom prosthetic replacement+ albendazole	no recurrence
1977/ Hooper (14)	43(M)	neck and trochanteric	18 M	Curettage+ bone grafts+ Dynamic Hip Screw+ Albendazole	no evidence of recurrence
	62(F)	Femur prox	119 M	prosthesis+PMMA+ Debridement	no evidence of disease

Year/ Author	Age(year)/sex	Site/side	Follow-up	Treatment	Outcome
2001/ Yildiz (15)	33(M)	Femur prox +iliac bone	127 M	curettage; grafting+PMMACustom-made prosthesis+PMMA	no evidence of disease
	42(M)	Femur prox	72 M	curettage +PMMA+internal fixation	There is no evidence of disease
	29(F)	Femur prox	lost to follow-up	Excision+custom-made partial prosthesis+PMMA	drop-out in follow-up
2001/Tomak (2)	17(F)	femoral neck to the whole diaphysis	6 Y	Curettage, cementation, albendazole	No recurrence
2009/ Neogi (16)	35(F)	femoral diaphysis	26 M	Resection, albendazole, cementation, internal fixation (step 1); allografting, chemotherapy (step 2), internal fixation	No recurrence
2015/ Muscolo (17)	65(F)	femoral diaphysis	9 Y	Resection+ intercalary bone allograft+ locked intramedullary nail	no signs of recurrence
	33(F)	proximal femur	6 Y	proximal femur allograft prosthesis composite+ dynamic compression plate	no signs of recurrence
2016/ Goldenitsch (5)	44(M)	proximal femur	17 M	resection +albendazole	no evidence of recurrence
2018/Gautam (18)	25(M)	femoral diaphysis	2 Y	Curettage+resection+interlockingnail+ allograft +Albendazole+praziquantel	the patient is doing well

Conclusion

It seems that the definitive treatment of femoral bone hydatid cysts is not surgical resection and intramedullary nail placement alone. In addition to resection of the cyst, the infected area should be removed extensively and the defected area, if needed, covered by cement or bone allograft. Regular chemotherapy may play a key role in post-operative treatment. Finally, it is worth noting that orthopedic surgeons should be aware of this type of pathological fracture. It can be concluded that paying attention to the long-term complications of fractures requires educational considerations during the professional performance of surgeons.

Acknowledgments

None.

Conflict of Interest

The authors declare no conflict of interest.

References

- Mattern CJ, Gardner MJ, Grose A, Helfet DL. Echinococcus disease of the bone presenting as a femoral shaft non-union. Clin Orthop Relat Res. 2007; 458:220-5. [DOI:10.1097/BLO.0b013e31802ff823] [PMID]
- Tomak Y, Dabak N, Gulman B, Karaismailoglu TN, Basoglu T, Incesu L. Hydatid disease of the left femur: A case report bulletin. Hospital Joint Disease. 2002;60(2):89-93.
- Rasoulia E, Zibaei M, Firoozeh F. Multivesicular hydatid cyst of the kidney. Rev Soc Bras Med Trop, 2019; 52:e20180374. [DOI:10.1590/0037-8682-0374-2018] [PMID]
- Mozafari M, Abdi M, Safaei A, Torkmandi H. Educational view in legal and ethical responsibility of physicians in Erb-Duchenne palsy: A case report. Int J Med Toxicol Forensic Med. 2022;13(1):37665.
- Goldenitsch E, Machacek F, Ritschl A. An uncommon cause of soft tissue mass of the extremities, report of 2 cases and review of literature of cystic Echinococcosis. Primary Health Care. 2016; 6(2):225-230. [DOI:10.4172/2167-1079.1000225]
- Srinivas MR, Deepashri B, Lakshmeesha MT. Imaging spectrum of hydatid disease: usual and unusual locations. Pol J Radiol. 2016; 81:190-

205. [DOI:10.12659/PJR.895649] [PMID] [PMCID]
7. Canoville D, Hannebicque M, Rochcongar G, Michon J, Dumaine V, Hulet Ch. Successful pelvic resection for acetabularhydatidosis. Case Rep Orthop. 2017; 3:1-12. [DOI:10.1155/2019/2942858] [PMID] [PMCID]
8. Babitha F, Priya P, Poothiade U, et al. Hydatid cyst of bone. Indian J Med Microbiol. 2015;33(3): 442-51. [DOI:10.4103/0255-0857.158587] [PMID]
9. Maillou M, Tojeiro Ch, López-Vélez S. Management of osseous cystic echinococcosis. Exp Rev Anti-Infect Ther. 2017; 15:12: 1075-82. [DOI:10.1080/14787210.2017.1401466] [PMID]
10. Booz M K. The management of hydatid disease of bone and joint. J Bone Joint Surg. 1972; 54 (4): 698-709. [DOI:10.1302/0301-620X.54B4.698]
11. Dehkordi A, Sanei B, Yousefi M, et al. Albendazole and treatment of hydatid cyst: review of the literature. Infect Disord Drug Targets. 2019; 19(2): 101-4.
12. Belzunegui J, Maiz O, Lopez L, Plazaola I, Gonzalez C, Figueroa M. Hydatid disease of bone with adjacent joint involvement. A radiological follow-up of 12 years. Br J Rheumatol, 1997; 36(1): 133-5. [DOI:10.1093/rheumatology/36.1.133] [PMID]
13. Natarajan S, Manoli S, Pradeep S, Basnyat, Clive J. Bransom, Roderick D.B. Jones. Spontaneous rupture of primary musculoskeletal hydatid cyst. Image Surg. 2002; 132(3) 533-534. [DOI:10.1067/msy.2002.118713] [PMID]
14. Hooper J, Mclean I. Hydatid disease of the femur. Report of a case. J Bone Joint Surg. 1977; 59 (7):974-76 [DOI:10.2106/00004623-197759070-00026] [PMID]
15. Yildiz Y, Bayrakci K, Altay M, Saglik Y. The use of polymethylmethacrylate in the management of hydatid disease of bone. J Bone Joint Surg Br. 2001;83(7):1005-8. [DOI:10.1302/0301-620X.83B7.0831005] [PMID]
16. Neogi DS, Kumar V, Malhotra R. Femoral allograft in the management of osseous hydatidosis presenting as femoral shaft non-union. Arch Orthop Trauma Surg. 2009; 129, 1627-32. [DOI:10.1007/s00402-008-0797-1] [PMID]
17. Muscolo DL, Zaidenberg EE, Farfalli GL, Aponte-Tinao LA, Ayerza MA. Use of massive allografts to manage hydatid bone disease of the femur. orthopedics. 2015;38(10):e943-6. [DOI:10.3928/01477447-20151002-92] [PMID]
18. Gautam D, Malhotra R, Dubey S. Combination drug chemotherapy and massive skeletal allograft in the management of hydatid disease of femur. Case Reports. 2018. [DOI:10.1136/bcr-2017-223332] [PMID] [PMCID]

How to Cite This Article:

Farzam R, Abdi M, Farhangi M, Zibaei M, Torkmandi H. Educational view of Pathological Fracture of Femur due to Hydatid Cysts: A Case Report and Review of Literature, J Adv Med Biomed Res. 2022; 30(141): 374-8.

Download citation:

[BibTeX](#) | [RIS](#) | [EndNote](#) | [Medlars](#) | [ProCite](#) | [Reference Manager](#) | [RefWorks](#)

Send citation to:

 [Mendeley](#)  [Zotero](#)  [RefWorks](#) [RefWorks](#)