

Death from Hemophagocytic Lymphohistiocytosis Syndrome Due to Generalized Hemorrhage

Vahid Kaveh¹, Shahin Keshtkar Rajabi*²


1. Dept. of Medical Oncology and Hematology, Iran University Of Medical Sciences, Tehran, Iran
2. Dept. of Internal Medicine, Firoozgar Hospital, Iran University Of Medical Sciences, Tehran, Iran

Article Info

 10.30699/jambs.28.127.119

Received: 2019/11/27;
Accepted: 2020/02/01;
Published Online: 01 Mar 2020;

Use your device to scan and read the article online



ABSTRACT

Hemophagocytic lymphohistiocytosis (HLH) is the result of excessive cytokine release, leading to over-response by immune cells, such as macrophages and T lymphocytes. Here, we report a lethal case of HLH with a complete clinical course. The patient was a 45-year-old man with fever and chills since two months ago plus splenomegaly, hepatomegaly, and pancytopenia. The Anti-HBc IgM was positive, but the HBS antigen, anti-HCV, and HBS antibody were negative. Assessment for cirrhosis was carried out by FibroScan, which showed F4 grade. The biopsy sampling was impossible due to the low platelet count. During admission, generalized bleeding was developed and led to alveolar hemorrhage, which subsequently resulted in the patient's death. Liver necropsy certified the diagnosis of hemophagocytic syndrome. Overall, according to the reported case in this paper, it should be remembered that secondary HLH is an inflammatory phenomenon due to different conditions, such as latent newly-developed infections.

Keywords: Diagnosis, Epidemiology, Hemophagocytic lymphohistiocytosis

Corresponding Information:

Shahin Keshtkar Rajabi: Dept. of Internal Medicine, Firoozgar Hospital, Iran University of Medical Sciences, Tehran, Iran **E-mail:** sh_rajabi64@yahoo.com



Copyright © 2019, This is an original open-access article distributed under the terms of the Creative Commons Attribution-noncommercial 4.0 International License which permits copy and redistribution of the material just in noncommercial usages with proper citation.

Introduction

Hemophagocytic lymphohistiocytosis (HLH) is the result of excessive cytokine release, leading to over-response by immune cells, such as macrophages and T lymphocytes (1–3). Primary and secondary types are the HLH subtypes (4). Definite diagnosis is difficult due to various manifestations (5, 6). Severe hyperinflammation is developed by activated macrophages and T lymphocytes (6). Children are usually affected by primary HLH versus secondary HLH in adults (7). Due to life-threatening consequences, HLH should be diagnosed and treated promptly to attain the best prognosis, especially in secondary cases (8). The case fatality rate of HLH is approximately 10% and is usually due to generalized visceral bleeding (6). However, the mortality in some treatment-focused studies with a larger sample population ranged from 20% to 88% (9). Here, we report a lethal case of HLH with a complete clinical course.

Case Report

The patient was a 45-year-old male subject with fever and chills since two months ago without any specific circadian patterns. At initial admission, the body temperature was 38°C by oral measurement, and there was splenomegaly in clinical examination, which

was detected by ultrasound as huge splenomegaly (diameter 84*205) plus hepatomegaly (span 155 mm). Normal liver size is 10.5 cm in men and 7 cm in women, and the spleen's largest size is 12–14 cm. Both kidneys had increased echo pattern with corticomedullary contrast, suggesting acute tubular necrosis. There was free fluid accumulation in pelvic and perihepatic regions. Also, there was a right-sided pleural effusion with a thickness of 188 mm.

The Cytomegalovirus (CMV), Epstein-Barr virus (EBV), and Tuberculosis were assessed and ruled out. Lumbar puncture was not possible due to the low platelet count. The initial body temperature was 38°C and was up to 39°C during admission. Due to the inappropriate condition of the patient, the transfer was impossible. However, a computed tomography (CT) scan of various parts, presented by the patient, was total without any evidence of malignancy. Bone marrow aspiration and biopsy were normal, and macrophage was not seen. There were pancytopenia, high serum creatinine, and blood urea nitrogen, high (over 2000 mg/dl) lactate dehydrogenase (LDH), hyperuricemia, and abnormal liver enzyme, as well as bilirubin levels, in laboratory assessment.

The leukocyte count was as low as 1500 per mm³ at admission, and after one week reached 6800 per mm³.

In protein electrophoresis, the albumin and alpha 1 proteins had low levels, but alpha 2 and gamma proteins had high levels. C-reactive protein (CRP) was positive, with a numerical amount of 15 mg/L, and erythrocyte sedimentation rate (ESR) was high (41 mm/hr). The urinalysis showed 3+ and 4+ protein and blood in urine samples besides leukocyturia and mild bacteriuria. Venous blood gas analysis showed low Partial Pressure of Carbone Dioxide (PCO₂), Base excess (BE), and Bicarbonate (HCO₃) plus a high Partial Pressure of Oxygen (PO₂) level. The anti-double stranded test (Anti-dsDNA), Liver kidney microsome antibodies (Anti-LKM), Anti-smooth muscle antibody test (ASMA), Antinuclear Antibodies (ANA), Antineutrophil cytoplasmic antibodies (P-ANCA, and C-ANCA) were all negative. The infectious causes for pancytopenia and huge splenomegaly, such as endocarditis, brucellosis, HIV infection, and leishmaniasis, were ruled out. The Anti-HBC IgM was positive, but the HBS antigen, anti-HCV, and HBS antibody were negative. A high procalcitonin level (7.9 ng/ml) was also seen.

Assessment for cirrhosis was done by Liver Elastography (FibroScan), which showed F4 grade and indicated the need for a liver biopsy by IQR/Med

ratio of 20%. However, the biopsy sampling was impossible due to the low platelet count (113000 and 56000 per mm³ at admission and after one week, respectively) and postponed till the normalization of the platelet count. The international normalized ratio (INR) was 1.2, and Partial Thromboplastin Time (PTT) was as long as 60 s. One of the proposed differential diagnoses was a hemophagocytic syndrome. Accordingly, the ferritin and triglyceride levels were assessed. Also, the bone marrow biopsy was carried out to assess the macrophage aggregation, but it was negative. Dexamethasone was prescribed for the patient because of the high suspicion of hemophagocytic syndrome.

During admission, generalized bleeding was developed and led to alveolar hemorrhage, which subsequently resulted in the patient's death. Liver necropsy showed that there were many macrophages, and the diagnosis was by standard clinical criteria by the American Pathology Association ([Figure 1](#)). Regarding high fever, splenomegaly, pancytopenia, high ferritin, and high number of macrophages in necropsy, the patient had five out of eight criteria, and it was established by a hematologist.

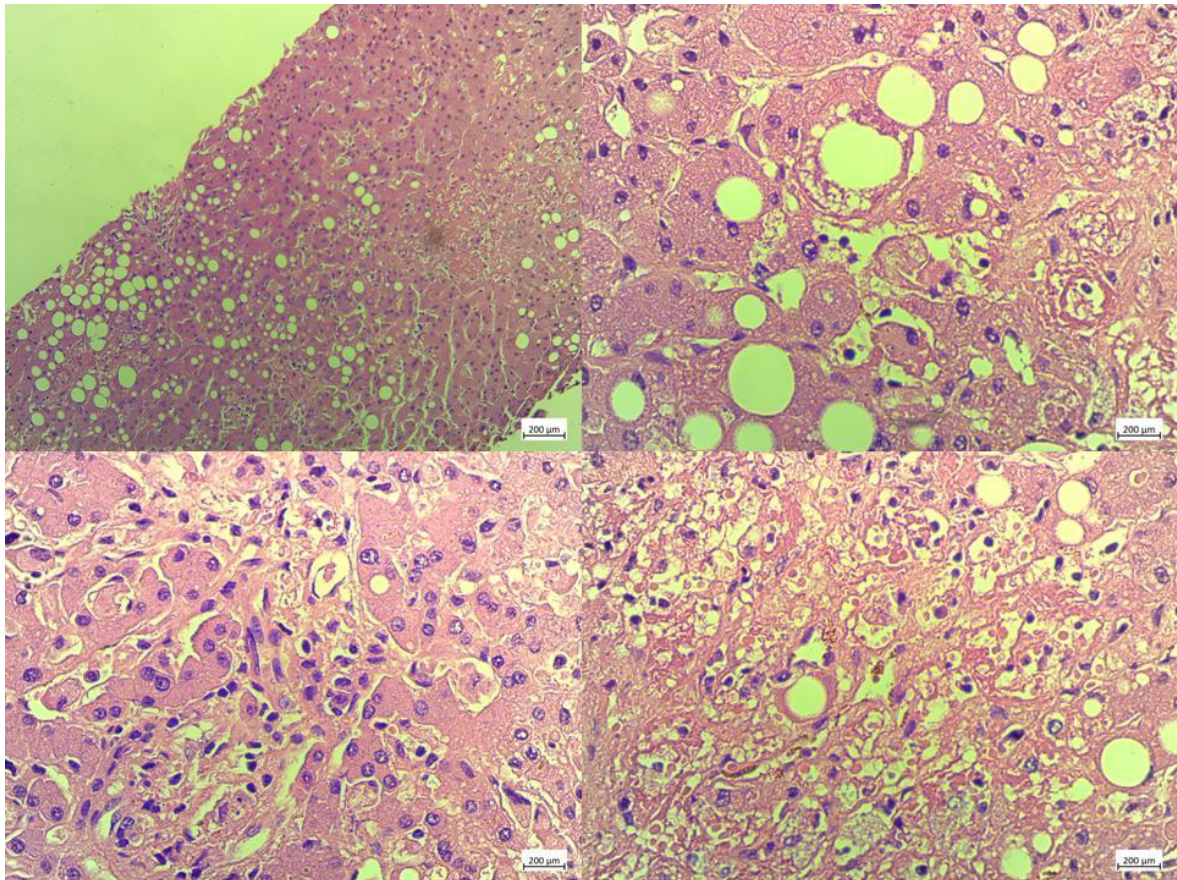


Figure 1. Histopathological results of liver necropsy; there are many macrophages in the tissue

Table 1. The classification of superficial palmar arches according to Coleman and Anson (from references 9)

Test	Amount	NL
ANA	1/40	Up to 1/80
ESR	41	<15
CRP	15	<3
Anti-DS DNA	2	<30
ASMA	-	-
P-ANCA	0.3	<5
C-ANCA	1.2	<5
Wright	1/20	>1/80
BUN	75	7-20
Cr	3.5	0.8-1.4
Uric acid	6	3.4-7
LDH	2400	140-280
AST	250	10-40
ALT	362	7-56
ALP	368	20-140
Bil T	4.6	0.2-1.2
Bil D	2.8	
INR	1.2	< 1.1
PTT	60	40-50
Ferritin	680	12-300
TG	183	<150
Procalcitonin	7.9	0.1-0.44

Discussion

HLH is a potentially life-threatening condition with triggering pre-inflammatory factors. The middle-aged male patient, reported in this paper, had a two-month history of fever and chills and nearly the ten-day course of final life process from the hospital admission to final death. Dhawale *et al.* (10) reported an 18-year-old Indian male patient presenting with a two-month history of fever, generalized weakness, and weight loss, as seen in our patient. The diagnosed condition was established by the HLH-2004 criteria in their study. In their report, the patient was survived after that the pleural fluid was assessed microbiologically, and the presence of mycobacterium tuberculosis was demonstrated and led to standard therapy.

Our patient had a positive result for anti-HBc IgM, suggesting a possible etiological role for hepatitis B infection. However, the only used treatment was dexamethasone that showed no life-saving effect and possibly led to further provocation of disease. Regarding high suspicion, high dose dexamethasone with a dose of 40 mg/day was initiated. Because of no definite diagnosis and incomplete criteria, as well as no satisfaction among the patient's relatives, chemotherapy was not initiated.

Diagnostic criteria for HLH should minimally include the presence of five out of the eight criteria,

including fever, splenomegaly, cytopenia (anemia, thrombocytopenia, and neutropenia), hypertriglyceridemia or hypofibrinogenemia, hemophagocytosis in body organs without malignancy, low activity in natural killer cells, increased ferritin, and high CD25 (11–13). However, less than five criteria were found in our study that led to delayed diagnosis despite high suspicion.

Thomas *et al.* (14) reported five HLH cases with the expiration of four patients. One of the patients was died due to generalized hemorrhage, such as our reported case. The background conditions in their patients were immunological, infectious, and malignancies, showing the importance of the completion of diagnostic approaches in our study to detect the definite primary etiology. However, the recognition of background etiology would result in a further chance of treatment and life-saving attempts.

Furthermore, Ferreira *et al.* (15) reported seven cases of HLH that led to two fatal cases. Also, the primary infections were Epstein–Barr virus, cytomegalovirus, and leishmaniasis in three, one, and two cases, respectively, with one idiopathic case. Aleem *et al.* (16) reported a patient that found to have evidence of chronic hepatitis B infection according to the serological tests and liver biopsy.

However, the patient in our study had acute hepatitis B infection according to positive IgM levels of anti-HBc antibody. Also, Halfon *et al.* (17) reported a case of HLH due to acute Cytomegalovirus and Hepatitis-B Virus sexual co-infection, but the reported case in our study had no clear route of acquisition of hepatitis B infection. In Iran, a study by Shamsian *et al.* (18) reported six cases of primary HLH and their outcome from a single tertiary-care center in Tehran.

Conclusion

Totally, according to the reported case in this paper, it is concluded that secondary HLH is an inflammatory phenomenon due to different conditions, such as latent newly-developed infections. The patients would have a better prognosis if diagnosed and treated promptly with the goal-oriented treatment of background disease.

Acknowledgment

The authors thank all those who helped them in writing this paper.

Conflict of Interest

The authors declared that there is no conflict of interest regarding the publication of this case report.

References

- George MR. Hemophagocytic lymphohistiocytosis: review of etiologies and management. *J Blood Med.* 2014;5:69-86. [DOI:10.2147/JBM.S46255]
- Janka GE, Lehmborg K. Hemophagocytic lymphohistiocytosis: pathogenesis and treatment. *Hematology Am Soc Hematol Educ Program.* 2013;2013:605-11. [DOI:10.1182/asheducation-2013.1.605]
- Fisman DN. Hemophagocytic syndromes and infection. *Emerg Infect Dis.* 2000;6(6):601-8. [DOI:10.3201/eid0606.000608]
- Grzybowski B, Vishwanath VA. Hemophagocytic Lymphohistiocytosis: A diagnostic conundrum. *J Pediatr Neurosci.* 2017;12(1):55-60. [DOI:10.4103/jpn.JPN_140_16]
- Filipovich AH. Hemophagocytic lymphohistiocytosis (HLH) and related disorders. *Hematology Am Soc Hematol Educ Program.* 2009:127-31. [DOI:10.1182/asheducation-2009.1.127]
- Morimoto A, Nakazawa Y, Ishii E. Hemophagocytic lymphohistiocytosis: Pathogenesis, diagnosis, and management. *Pediatr Int.* 2016;58(9):817-25. [DOI:10.1111/ped.13064]
- Shah AR, Muzzafar T, Assi R, et al. Hemophagocytic lymphohistiocytosis in adults: An under recognized entity. *BBA Clin.* 2016;7:36-40. [DOI:10.1016/j.bbacli.2016.12.002]
- Bhatt NS, Oshrine B, An Talano J. Hemophagocytic lymphohistiocytosis in adults. *Leuk Lymphoma.* 2018:1-10. [DOI:10.1080/10428194.2018.1482543]
- Hayden A, Park S, Giustini D, Lee AY, Chen LY. Hemophagocytic syndromes (HPSs) including hemophagocytic lymphohistiocytosis (HLH) in adults: A systematic scoping review. *Blood Rev.* 2016;30(6):411-20. [DOI:10.1016/j.blre.2016.05.001]
- Dhawale MS, Joshi AR, Bhatkule MA, Kumbhakarna NR, Bindu RS. Hemophagocytic syndrome. *Indian J Hematol Blood Transfus.* 2014;30(Suppl 1):9-11. [DOI:10.1007/s12288-012-0217-0]
- Chute DJ, Rawley J, Cox J, Bready RJ. Sudden unexpected death due to hemophagocytic lymphohistiocytosis syndrome. *J Forensic Sci.* 2013;58(4):1080-4. [DOI:10.1111/1556-4029.12131]
- Ullah W, Abdullah HM, Qadir S, Shahzad MA. Haemophagocytic lymphohistiocytosis (HLH): a rare but potentially fatal association with *Plasmodium vivax* malaria. *BMJ Case Rep.* 2016;2016. [DOI:10.1136/bcr-2016-215366]
- Zhang Z, Wang J, Ji B, et al. Clinical presentation of hemophagocytic lymphohistiocytosis in adults is less typical than in children. *Clinics (Sao Paulo).* 2016;71(4):205-9. [DOI:10.6061/clinics/2016(04)05]
- Thomas D, Shah N, Patel H, Pandya T, Gauchan D, Maroules M. Hemophagocytic Lymphohistiocytosis: A series of five clinical cases in adult patients at a single institution with a review of the literature. *N Am J Med Sci.* 2015;7(9):415-20. [DOI:10.4103/1947-2714.166225]
- Ferreira DG, do Val Rezende P, Murao M, Viana MB, de Oliveira BM. Hemophagocytic lymphohistiocytosis: a case series of a Brazilian institution. *Rev Bras Hematol Hemoter.* 2014;36(6):437-41. [DOI:10.1016/j.bjhh.2014.07.003]
- Aleem A, Al Amoudi S, Al-Mashhadani S, Siddiqui N. Haemophagocytic syndrome associated with hepatitis-B virus infection responding to etoposide. *Clin Lab Haematol.* 2005;27(6):395-8. [DOI:10.1111/j.1365-2257.2005.00728.x]
- Halfon P, Retornaz F, Mathieu D, Helbert T, Philibert P, Pégliasco H. Virus-associated hemophagocytic syndrome related to acute CMV and HBV sexual co-infection: a case report. *J Clin*

Viol. 2009;46(2):189-91.
[DOI:10.1016/j.jcv.2009.07.001]

18. Shamsian BS, Rezaei N, Alavi S, et al. Primary hemophagocytic lymphohistiocytosis in Iran: report

from a single referral center. *Pediatr Hematol Oncol.* 2012;29(3):215-9.

[DOI:10.3109/08880018.2012.657338]

How to Cite This Article:

Kaveh V, Keshtkar Rajabi S. Death from Hemophagocytic Lymphohistiocytosis Syndrome Due to Generalized Hemorrhage. *J Adv Med Biomed Res.* 2020; 28 (127) :119-123

Download citation:

[BibTeX](#) | [RIS](#) | [EndNote](#) | [Medlars](#) | [ProCite](#) | [Reference Manager](#) | [RefWorks](#)

Send citation to:

 Mendeley  Zotero  RefWorks [RefWorks](#)