Case Report Article | J Adv Med Biomed Res. 2025; 33(161): 372-378

Category: Clinical Medicine | Peer Reviewed | Open Access

Journal of Advances in Medical and Biomedical Research | ISSN:2676-6264

Life-Threatening Autonomic Dysregulation and Bulbar Neurological Deficits in Foodborne Botulism: A Case Report

Behzad Bijani, Abbas Allami*, AliReza Nikoonejad, Sara Nazemsadati

Department of Infectious Diseases, Clinical Research Development Unit, BuAliSina Hospital, Qazvin University of Medical Sciences, Qazvin, Iran

Article Info

10.22034/jambr.33.161.372

Received: 2025/06/11;
Accepted: 2025/10/06;
Published Online: 12 Dec 2025;

Use your device to scan and read the article online

***Corresponding author:**
Abbas Allami,
Department of Infectious Diseases, Clinical Research Development Unit, BuAliSina Hospital, Qazvin University of Medical Sciences, Qazvin, Iran

Email: allami9@yahoo.com

ABSTRACT

This case report describes a 17-year-old female patient who presented with severe autonomic dysregulation and neurological symptoms. We explain in detail the patient's clinical course, diagnostic evaluation, treatment, and follow-up, emphasizing the importance of early recognition and management of botulism. This case highlights the importance of public education on food safety practices to prevent future occurrences. The report also highlights the critical role of interdisciplinary collaboration in the management of complex cases involving multiple systems, such as the autonomic and neurological systems.

Keywords: Botulism, Foodborne Diseases, Bulbar Paralysis, Respiratory Insufficiency, Case Report

Copyright © 2025, This is an original open-access article distributed under the terms of the Creative Commons Attribution-noncommercial 4.0 International License which permits copy and redistribution of the material just in noncommercial usages with proper citation.

1. Introduction

Botulism is a rare but potentially fatal condition caused by the neurotoxin produced by *Clostridium botulinum,* most commonly acquired via ingestion of improperly preserved or canned food (1). The neurotoxin affects the peripheral nervous system, leading to a range of symptoms that can escalate rapidly, including cranial nerve dysfunction, autonomic instability, and respiratory failure (2). Botulism can manifest in several forms, including foodborne, wound, infant, and iatrogenic, with foodborne botulism being the most common form (3). Despite advancements in food safety, foodborne botulism is often associated with home canning practices, particularly in regions with traditional food preparation methods (4).

The pathophysiology of botulism involves inhibition of acetylcholine release at neuromuscular junctions, disrupting both somatic and autonomic nervous system functions (5). Symptoms can include cardiovascular instability, such as hypotension or hypertension, and gastrointestinal symptoms like constipation and ileus (3). Autonomic dysfunction manifests as labile blood pressure, tachycardia, and gastrointestinal dysmotility, which can complicate the clinical picture and require careful monitoring and management (6).

The clinical presentation of botulism can vary significantly depending on the amount of toxin ingested and the individual's susceptibility. Early symptoms may include nausea, vomiting, and abdominal cramps, which can easily be mistaken for other gastrointestinal illnesses

(7). As the disease progresses, neurological symptoms such as diplopia, dysphagia, and descending paralysis starting with cranial neuropathy become more prominent. The rapid progression of symptoms necessitates swift clinical intervention to mitigate the potential for severe complications, including respiratory failure and death (8).

Moreover, the increasing prevalence of home canning and the associated risks highlight the importance of public education on safe food-handling practices. Many individuals engage in home canning without adequate knowledge of food safety guidelines, which can lead to botulism outbreaks. This case illustrates the critical need for awareness regarding food safety, especially in home-prepared canned goods, and highlights the importance of prompt diagnosis and intervention (9). This report describes a rare case of botulism with profound autonomic instability requiring intensive support, illustrating the diagnostic and management challenges.

3. Case Presentation

A 17-year-old female presented to the emergency department with complaints of blurred vision, dizziness, diplopia, and dysphagia. These symptoms began five days before admission and progressively worsened, prompting her to seek medical attention. Notably, the patient had consumed canned green peas prepared in a bain-marie (heated in simmering water at approximately 80-90°C for 1-3 hours, without pressure cooking) two days before the onset of symptoms, and the peas were consumed without additional boiling or heating. The bain-marie method does not reach temperatures sufficient to kill Clostridium botulinum spores, which require 121°C under pressure for destruction. Additionally, she attended a gathering where several friends exhibited similar symptoms, raising concerns about potential foodborne illness. Upon admission, the patient demonstrated severe autonomic dysregulation, characterized by blood pressure readings of 180/120 mmHg and a heart rate of 145 beats per minute. The patient exhibited an absent peripheral pulse, altered consciousness, marked diaphoresis, and cranial nerve deficits, including ptosis and facial weakness. Neurological examination revealed significant muscle weakness, particularly in the proximal muscles, which further supported the suspicion of foodborne botulism. No scars or wounds were noted on physical examination, ruling out wound botulism.

The patient's medical history was unremarkable, with no previous episodes of similar symptoms, no significant past medical history, and no known allergies. She was not on any chronic medications, had no history of smoking or substance abuse, and her family history was negative for neurological or autoimmune disorders, or infectious disorders, including no familial cases of botulism or similar illnesses. Detailed clinical assessments included serial vital signs monitoring, showing fluctuations from hypertension (180/120 mmHg) to hypotension (80/50 mmHg), a full neurological exam confirming symmetric descending flaccid paralysis, and autonomic signs such as diaphoresis and tachycardia. During hospitalization, her condition deteriorated, with autonomic dysregulation manifesting as fluctuations in vital signs. Initially hypertensive, her blood pressure later dropped to 80/50 mmHg, and she developed signs of respiratory distress, necessitating immediate intervention.

Differential diagnosis included myasthenia gravis, Guillain-Barré syndrome, multiple sclerosis, and other neurologic disorders. These were ruled out based on acute onset following ingestion of suspect food, symmetric descending paralysis (unlike the ascending in Guillain-Barré), absence of relapsing-remitting features (as in multiple sclerosis), and lack of fatigable weakness. Cerebrospinal fluid examination, nerve conduction studies, electromyography, and Tensilon test were not performed, as the diagnosis was confirmed by toxin detection.

The multidisciplinary team, including infectious disease specialists and neurologists, collaborated to determine the best course of action for this complex case. The patient was admitted to the Intensive Care Unit (ICU) for close monitoring and management. Key interventions included intubation to secure the airway and provide respiratory support due to the risk of respiratory failure. Diagnostic workup included imaging and laboratory tests.

Initial laboratory studies demonstrated significant leukocytosis (WBC 13.8 $\times 10^3/\mu L$; Table 1) with otherwise normal hematologic parameters.

Inflammatory markers showed ESR = 3 mm/h (normal 0-20 mm/h) and CRP = 95 mg/dl (normal <6 mg/dl), indicating an inflammatory process possibly related to co-infection or aspiration. Serial arterial blood gas analysis showed a progression from severe respiratory acidosis at ICU admission (pH 7.16, pCO_2 61 mmHg, pO_2 36 mmHg) to a compensated metabolic alkalosis by 24 hours (pH 7.43, HCO_3^- 18.7 mEq/L; Table 2). The evolving acid-base disturbance was characterized by primary respiratory acidosis followed by compensatory metabolic alkalosis, with persistent hypoxemia throughout the clinical course. The initial respiratory acidosis (pH 7.16, pCO_2 61 mmHg) suggested acute ventilatory failure, potentially due to neuromuscular weakness, and severe pulmonary pathology. The subsequent normalization of pH with inappropriately low bicarbonate (18.7 mEq/L) indicated a superimposed metabolic acidosis. The persistent hypoxemia necessitated urgent evaluation for possible pulmonary pneumonia or acute respiratory distress syndrome.

A chest CT scan without contrast (Fig. 1) revealed ground-glass opacities in peripheral lung regions, mild cardiomegaly, bilateral pleural effusion, and consolidation in the lower lobes, suggestive of possible viral (COVID-19 involvement) or bacterial pneumonia, aspiration pneumonia, pulmonary edema, or acute respiratory distress syndrome (ARDS).

A brain CT scan without contrast showed diffuse bilateral cerebral edema with effacement of sulci and ventricles, raising concerns for increased intracranial pressure. A reference laboratory confirmed the presence

of Botulinum toxin A in the suspected food using a qualitative enzyme-linked immunosorbent assay (ELISA) test. Additionally, real-time reverse transcription PCR testing for SARS-CoV-2 (using standard primers targeting the RdRp and E genes per WHO protocols) was performed due to concurrent hypoxemia (SpO_2 53.1% on room air) and active community COVID-19 outbreaks during the patient's ICU admission, with results returning negative. The PCR was for general SARS-CoV-2 RNA detection, without variant subtyping. Toxicology screening returned negative results for common intoxicants.

The combination of severe autonomic instability and neurological symptoms raised concerns for foodborne botulism, necessitating a comprehensive diagnostic evaluation. Administration of botulinum antitoxin was initiated as soon as the diagnosis was confirmed, a crucial step for neutralizing circulating toxins and preventing further neurological damage. The patient received intravenous fluids for hydration, nutritional support via enteral feeding, and continuous monitoring of vital signs and neurological status. A multidisciplinary team, including infectious disease specialists, neurologists, and critical care physicians, was involved in her care to address the complexities of her condition.

The patient demonstrated gradual improvement throughout hospitalization. After 72 hours, she was successfully extubated and transitioned to a general ward for continued recovery. By the time of discharge, the patient was in stable condition with good general health and stable vital signs. Follow-up evaluations indicated a return to baseline neurological function, although some mild residual weakness persisted.

During her recovery, physical therapy was initiated to address muscle weakness and improve mobility. The patient participated in a structured rehabilitation program focusing on strength training and coordination exercises. The patient made a complete recovery without any sequelae.

The Table 3 summarizes the key clinical and diagnostic data, aiding in understanding the patient's condition and management.

Table 1. Complete Blood Count (CBC) Results at Hospital Admission.

CBC	10/15/2023	10/17/2023	10/20/2023	10/22/2023	10/25/2023	Unit	Normal Range
WBC	13.5*	13.8*	6.8	6.3	6.5	$x10^9$/L (or cells/uL)	4.0-10.0
RBC	5.41	5.46	3.80	3.80	3.90	$x10^{12}$/L (or cells/uL)	4.2-5.4
Hb	15.8	16.7	11.3†	11.2†	11.7†	g/dL	12.5-15.3
HCT	47.0	49.8	33.2	34.1	35.2	%	35.9-44.6
MCV	86.9	91.2	87.4	89.7	90.3	fL	77-98
MCH	29.2	30.6	29.7	29.5	30	pg	26-32
MCHC	33.6	33.5	34.0	32.8	33.2	g/dL	32-36
Plt	167	258	144	178	279	$x10^9$/L (or platelets/uL)	150-450
L	5	4	7	7	12	%	20-40
N	87‡	88‡	87‡	85‡	75	%	40-60
MIX	8	8	6	8	13	%	11.5-15
RDW	12.1	12.4	13.1	12.3	12.1	%	11.5-14.5
PDW	13.5	14.6	16.3	15.2	13.0	%	8-16
MPV	10.6	10.9	11.2	11.2	10.3	fL	7.5-11.5

%: Percentage, *: leukocytosis, CBC: Complete Blood Count, HCT: Hematocrit, Hb: Hemoglobin, L: Lymphocyte, MCH: Mean Corpuscular Hemoglobin, MCHC: Mean Corpuscular Hemoglobin Concentration, MCV: Mean Corpuscular Volume, MIX: Mixed Cells (Eosinophils/Basophils/Monocytes), MPV: Mean Platelet Volume, N: Neutrophil, PDW: Platelet Distribution Width, Plt: Platelet Count, RBC: Red Blood Cell count, RDW: Red Cell Distribution Width, WBC: White Blood Cell count, fl: femtoliters, g/dL: grams per deciliter, pg: picograms, uL: microliter, †: Anemia, ‡: Neutrophilia

Table 2. Arterial Blood Gas (ABG) Analysis.

Event	Date	pH	pCO2	Event	Date	pH
Admitted to emergency department and then infectious disease ward	10/16/2023	7.363	28.0	97	15.9	97.4
Admitted to ICU, Severe autonomic dysregulation, Altered consciousness, Cranial nerve deficits, including ptosis and facial weakness	10/17/2023	7.160	61.1	36	22.2	53.1
	10/17/2023	7.034	88.5	69	23.6	81.9
	10/17/2023	7.430	27.8	60	18.7	91.9
	10/17/2023	7.383	32.7	29	19.5	55.0
	10/17/2023	7.457	29.8	42	21.0	81.0
	10/18/2023	7.558	21.3	82	19.0	97.7
	10/18/2023	7.506	23.4	63	18.5	94.3
	10/18/2023	7.543	20.3	60	17.5	94.2
	10/19/2023	7.563	20.8	136	18.8	99.5
	10/21/2023	7.540	37.2	129	32.0	99.3
Extubated and transferred to general ward	10/22/2023	7.485	38.4	117	28.9	98.9

Table 3. Summary of the patient's clinical findings and diagnostic results.

Name of genes	Betweenness centrality
Blood Pressure	180/120 mmHg initially, dropped to 80/50 mmHg
Heart Rate	145 beats per minute
Neurological Symptoms	Blurred vision, diplopia, dysphagia, muscle weakness
Autonomic Symptoms	Diaphoresis, absent peripheral pulse
Cranial Nerve Deficits	Ptosis, facial weakness
Chest CT Findings	Ground-glass opacities, mild cardiomegaly, bilateral pleural effusion, consolidation
Brain CT Findings	Diffuse bilateral cerebral edema, effacement of sulci and ventricles
Laboratory Tests	Positive for Botulinum toxin A

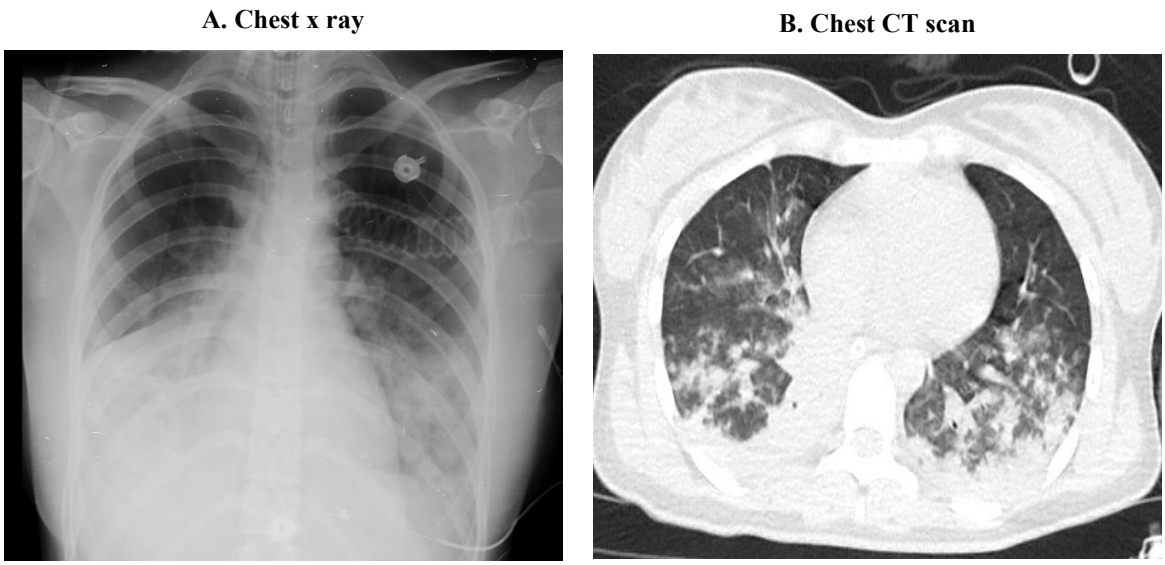

Figure 1. Chest X-ray and non-contrast chest computed tomography (CT) scan of the patient (**Prepared by Authors, 2025**).

3. Discussion

Autonomic dysregulation is a significant feature of botulism, primarily due to the action of the botulinum toxin on the peripheral nervous system. The toxin inhibits the release of acetylcholine at neuromuscular junctions, leading to muscle paralysis and affecting autonomic functions such as heart rate, blood pressure, and sweating (2). In this case, the patient exhibited significant autonomic instability, evidenced by severe hypertension and diaphoresis, highlighting the need for vigilant monitoring and management of autonomic symptoms in botulism cases (3).

The fluctuating blood pressure observed in this patient is consistent with the autonomic instability seen in botulism, where patients may experience episodes of hypertension followed by hypotension. This labile blood pressure can complicate the clinical picture, as aggressive treatment of hypertension may exacerbate hypotension. The management of such patients requires careful monitoring and a multidisciplinary approach to address both the neurological and autonomic components of the disease (10).

The presence of GGOs on a CT scan is a non-specific finding that can arise from various etiologies, particularly in a patient with botulism. Viral pneumonia is a primary consideration, with GGOs reflecting viral-induced inflammation and immune response (11). Bacterial superinfection, though less likely, could also contribute, especially in hospitalized patients, and is suggested by fever and elevated inflammatory markers. Botulism often impairs swallowing and cough reflexes due to cranial nerve involvement, increasing the risk of aspiration. This is particularly relevant given the patient's dysphagia, with CT findings potentially showing GGOs in dependent lung regions, such as the lower lobes, and consolidation (12). Also, autonomic dysregulation in botulism can lead to hemodynamic instability, potentially causing non-cardiogenic or cardiogenic pulmonary edema. This might manifest as GGOs with a perihilar distribution, accompanied by pleural effusions and cardiomegaly, as seen in the case. Clinical clues include signs of fluid overload or heart failure, which were not prominently noted but remain possible. Severe botulism or co-infection with COVID-19 can progress to ARDS, characterized by diffuse bilateral GGOs and consolidation on CT, reflecting widespread alveolar damage. This is suggested by severe hypoxemia and rapid respiratory deterioration, which were managed with intubation in this case (13). The interplay between these conditions is not well understood, but it highlights the need for comprehensive diagnostic evaluations, especially during pandemics, to differentiate between overlapping symptoms.

During the ICU stay, the patient developed acute confusion and depressed consciousness. Brain CT revealed diffuse cerebral edema, likely secondary to hypoxemia from respiratory paralysis and autonomic dysregulation-induced perfusion failure (blood pressure fluctuations: 180/120 mmHg to 80/50 mmHg). In severe botulism, brain edema may develop secondary to hypoxic injury from respiratory paralysis or autonomic dysregulation-induced perfusion failure. Immediate interventions included airway management (e.g., intubation for airway protection), blood pressure management, and botulinum antitoxin administration. Treatment involved early administration of botulinum antitoxin, which is essential for neutralizing circulating toxin and preventing further neurological damage. Supportive care, including mechanical ventilation and hemodynamic monitoring, was critical in managing the patient's respiratory failure and autonomic instability. The successful outcome, with the patient extubated after 72 hours and discharged after 14 days, underscores the importance of timely intervention, but the residual weakness highlights the potential for long-term sequelae (14).

From a public health perspective, this case underscores the risks associated with home canning, particularly the bain-marie method, which may not adequately eliminate *Clostridium botulinum* spores. As noted, the bain-marie's lower temperatures fail to kill spores, unlike pressure canning. The source of infection, home-canned green peas, aligns with epidemiological data showing that such practices are a major source of foodborne botulism outbreaks. Public health education and awareness campaigns are essential to reduce incidence, emphasizing proper canning techniques and the dangers of consuming improperly preserved foods. Also, the emotional and psychological impact of such a severe illness on both the patient and their family should not be overlooked. Patients recovering from botulism may experience anxiety and fear related to their health and the potential for recurrence. Providing psychological support and counseling can be beneficial in addressing these concerns, thereby facilitating a more comprehensive approach to patient care (15).

5. Conclusion

This report highlights the potential dangers associated with improperly prepared canned foods and the critical need for public awareness regarding safe food handling and preservation practices. The successful management of this case underscores the critical importance of a multidisciplinary approach in severe botulism, particularly when autonomic dysregulation is a dominant feature. The patient's favorable outcome (despite life-threatening cardiovascular instability and respiratory compromise) highlights the effectiveness of timely antitoxin administration and intensive supportive care. By adopting comprehensive public health strategies, enhancing clinical awareness, and promoting safe food practices, we can work towards preventing similar incidents and improving patient care in the face of emerging infectious diseases. Public health education on safe food handling practices, especially home canning, is crucial to prevent future incidents. This case serves as a reminder of the complexities involved in diagnosing and managing botulism, particularly in a world where food safety and infectious diseases are increasingly intertwined. Enhancing public education on validated preservation methods and clinical vigilance can help preventing future cases and ensure rapid intervention when botulism does occur.

6. Declarations

6.1 Acknowledgments

We extend our gratitude to the patient for their cooperation and participation in this study.

6.2 Ethical Considerations

Written informed consent was obtained from the patient for publication of this case report, including the use of anonymized clinical data and any accompanying images. All personal identifiers have been removed to protect patient confidentiality in accordance with privacy protection standards. The institutional ethics review committee granted an exemption for this case report as it involved retrospective analysis of existing medical records without any modification to standard care protocols. This report was prepared following the ethical guidelines outlined by the Committee on Publication Ethics (COPE) and adheres to the principles of the Declaration of Helsinki regarding medical research involving human subjects. This case report received approval from the Research Ethics Committee of Qazvin University of Medical Sciences (IR.QUMS.REC.1404.018).

6.3 Authors' Contributions

Behzad Bijani: Drafted the initial manuscript; conducted the literature review. AliReza Nikoonejad: Performed the literature review; edited the final draft for clarity and accuracy. Abbas Allami (Senior/Corresponding Author): Conceived and designed the case report; contributed to patient management; interpreted neurological findings; collected and analyzed clinical data; critically revised the manuscript for intellectual content. Sara Nazemsadati: Supervised the clinical case; validated the diagnostic findings; approved the final version for submission. All authors read and approved the final manuscript and agree to be accountable for all aspects of the work.

6.4 Conflict of Interest

The authors declare no conflict of interest.

6.5 Fund or Financial Support

This research received no external funding.

6.6 Using Artificial Intelligence Tools (AI Tools)

The use of artificial intelligence in the preparation of this manuscript was strictly limited to grammar and language editing. All scientific content, and interpretations were generated solely by the authors.

References

1. Mezencev R, Klement C. Foodborne botulism - a re-emerging public health challenge. Epidemiol Mikrobiol Imunol. 2017;66(1):39-48.
2. Rempel L, Malik RN, Shackleton C, Calderón-Juárez M, Sachdeva R, Krassioukov AV. From Toxin to Treatment: A Narrative Review on the Use of Botulinum Toxin for Autonomic Dysfunction. Toxins (Basel). 2024;16(2):96. [DOI:10.3390/toxins16020096] [PMID] [PMCID]
3. Kobaidze K, Wiley Z. Botulism in the 21st Century: A Scoping Review. Brown J Hosp Med. 2023;2(2):72707. [DOI:10.56305/001c.72707] [PMID] [PMCID]
4. Anniballi F, Auricchio B, Fiore A, Lonati D, Locatelli CA, Lista F, et al. Botulism in Italy, 1986 to 2015. Euro Surveill. 2017;22(24): 30550. [PMID] [PMCID] [DOI:10.2807/1560-7917.ES.2017.22.24.30550]
5. Connan C, Popoff MR. Uptake of Clostridial Neurotoxins into Cells and Dissemination. Curr Top Microbiol Immunol. 2017;406:39-78. [DOI:10.1007/82_2017_50] [PMID]
6. Thompson J, Horowitz Z, Blumenberg A. Botulism. J Educ Teach Emerg Med. 2021; 6(1):S1-s23. [DOI:10.5070/M561051827] [PMCID]
7. Min M, Bai L, Peng X, Guo L, Wan K, Qiu Z. An Outbreak of Botulinum Types A, B, and E Associated With Vacuum-Packaged Salted Fish and Ham. J Emerg Med. 2021;60(6):760-3. [DOI:10.1016/j.jemermed.2020.12.006] [PMID]
8. Bijani B, Allami A, Nikoonejad A. Botulism and Acidic Foods: A Case Report and Literature Review. Sci J Kurd Univ Med Sci. 2025;30(4):In press.
9. Khorasan MR, Rahbar M, Bialvaei AZ, Gouya MM, Shahcheraghi F, Eshrati B. Prevalence, Risk Factors, and Epidemiology of Food-borne Botulism in Iran. J Epidemiol Glob Health. 2020;10(4):288-92. [PMID] [PMCID] [DOI:10.2991/jegh.k.200517.001]
10. Miceli G, Cassataro G, Volpe V, Fertitta E, Canale C, Tomaiuolo L, et al. Postprandial hypotension as a predictor of respiratory failure in patients with foodborne botulinum intoxication - a case-control study in outbreak investigation. Int J Infect Dis. 2023;136:111-4. [DOI:10.1016/j.ijid.2023.09.014] [PMID]
11. Eslambolchi A, Maliglig A, Gupta A, Gholamrezanezhad A. COVID-19 or non-COVID viral pneumonia: How to differentiate based on the radiologic findings?. World J Radiol. 2020;12(12):289-301. [PMCID] [DOI:10.4329/wjr.v12.i12.289] [PMID]
12. Agarwala P, Machnicki S, Ryu JH, Hu X, Saez K, Raoof S. Imaging of Aspiration: When to Suspect Based on Imaging of Bacterial Aspiration, Chemical Aspiration, and Foreign Body Aspiration. InSeminars in Respiratory and Critical Care Medicine. 2024. New York, NY, USA: Thieme Medical Publishers, Inc.. [DOI:10.1055/s-0044-1791740] [PMID]
13. Selickman J, Vrettou CS, Mentzelopoulos SD, Marini JJ. COVID-19-Related ARDS: Key Mechanistic Features and Treatments. J Clin Med. 2022;11(16):4896. [PMID] [PMCID] [DOI:10.3390/jcm11164896]
14. Rao AK. Clinical guidelines for diagnosis and treatment of botulism, 2021. MMWR Recomm Rep. 2021;70(2):1-30. [PMID] [PMCID] [DOI:10.15585/mmwr.rr7002a1]
15. Hoang LH, Nga TT, Tram NT, Trang LT, Ha HTT, Hoang TH, et al. First report of foodborne botulism due to Clostridium botulinum type A(B) from vegetarian home-canned pate in Hanoi, Vietnam. Anaerobe. 2022;77:102514. [DOI:10.1016/j.anaerobe.2022.102514] [PMID]

How to Cite This Article:

Bijani B, Allami A, Nikoonejad A, Nazemsadati S. Life-Threatening Autonomic Dysregulation and Bulbar Neurological Deficits in Foodborne Botulism: A Case Report. J Adv Med Biomed Res. 2025;33(161):372-8.

Download citation:
BibTeX | RIS | EndNote | Medlars | ProCite | Reference Manager | RefWorks

Send citation to:
Mendeley Zotero RefWorks